



# Spotlight on Carcinosarcoma of the Ovary: A Scoping Review

Martina Gauci<sup>1,\*</sup>, Jean Calleja-Agius<sup>1</sup>

## ABSTRACT

Ovarian carcinosarcoma, also referred as malignant mixed Mullerian tumour, is an uncommon, highly aggressive and malignant neoplasm which makes up 1 to 4% of all ovarian tumours. It is biphasic involving both malignant sarcomatous (mesenchymal) and carcinomatous (epithelial) cells. There are various subtypes such as serous and endometrioid. However, the mesenchymal part is sarcomatous. About 90% of cases of ovarian carcinosarcoma spread outside the ovary. The two most accepted theories of origin for carcinosarcoma of the ovary are the collision and conversion theories. A third theory is the combination theory. Prognosis remains poor even when still localised in the ovary. In the last few years, there has been no change in the survival rate. The median survival rate is lower than 2 years. Clinical features mainly include lower abdominal pain and a palpable abdominal mass. Ovarian carcinosarcoma remains poorly understood and understudied. Being a rare tumour, elaborate therapeutic consensus is not available for ovarian carcinosarcoma. The main treatment involves cytoreductive surgery and then chemotherapy. The type of chemotherapy, role of radiotherapy and novel therapies need to be further studied. The main objective of this article is to review the current literature on carcinosarcoma of the ovary.

## KEYWORDS

malignant mixed Mullerian tumour; ovarian cancer; ovarian carcinosarcoma; cytoreductive surgery; chemotherapy

## AUTHOR AFFILIATIONS

<sup>1</sup> Department of Anatomy, Faculty of Medicine and Surgery, University of Malta, Malta

\* Corresponding author: Biomedical Sciences Building & Centre for Molecular Medicine and Biobanking, University of Malta, Msida MSD2080, Malta; e-mail: martina.gauci.21@um.edu.mt

Received: 4 November 2023

Accepted: 22 April 2024

Published online: 17 September 2024

Acta Medica (Hradec Králové) 2024; 67(1): 1–11

<https://doi.org/10.14712/18059694.2024.13>

© 2024 The Authors. This is an open-access article distributed under the terms of the Creative Commons Attribution License (<http://creativecommons.org/licenses/by/4.0>), which permits unrestricted use, distribution, and reproduction in any medium, provided the original author and source are credited.

## INTRODUCTION AND DEFINITION

Carcinosarcoma of the ovary, previously known as malignant mixed Mullerian tumour, is a specific type of ovarian cancer (1). The aim of this literature review is to compile an update on carcinosarcoma of the ovary.

Regarding cancer mortality in females, the 5th leading cause is ovarian cancer. Up to 4% of all malignant ovarian tumours are ovarian carcinosarcoma (2). Carcinosarcoma of the ovary is defined as a rare and highly aggressive epithelial malignancy. It is also described as being biphasic as it has mesenchymal and malignant epithelial components, thus described as being complex from a histological perspective (3–5). Only 10% of all cases are bilateral (6). It affects postmenopausal woman, the average median age varies between 60 and 70 years old (4, 6). Given its aggressive nature, prognosis is poor. Outcomes are diverse as some literature reported a median overall survival rate varying from 8 to 32 months while others stated that the median survival rate was less than 2 years (4, 6, 7). Treatments include cytoreductive surgery and adjuvant chemotherapy (4, 6). Since this is a rare type of cancer, research is lacking. Further research is needed to establish the early clinical signs and symptoms, molecular and genetic features to develop target novel therapies, role of radio- and chemotherapy and the best type of chemotherapy to use.

## METHODOLOGY

This is a review on ovarian carcinosarcoma. Literature reviews, case studies and original studies published in the English language, were used. For this literature review, multiple databases were used. A 10-year period (2013–2023) search with 'Free Full text' as filter on PubMed was carried out by typing, 'Ovarian carcinosarcoma' in the search box. More articles were selected on PubMed and Google Scholar by removing the 10-year period and 'Free Full text' filters. Further articles were retrieved and the results that came up were analysed according to citations, date and information given in the abstract. To ensure validity, when reading the articles, the references were also checked.

## EPIDEMIOLOGY

Ovarian carcinosarcoma makes up about 1–4% of all ovarian tumours (8–10). It has been reported that ovarian carcinosarcoma is more prevalent in Afro-Americans (1). Also, studies in Israel showed that gynaecological malignancies including ovarian carcinosarcoma are more common in the Jewish rather than Arab population (13). This might be due to large population of Jews or that Jewish population are older during first birth and have less parity rates compared with Arabs (11, 12). Moreover, ovarian carcinosarcoma is diagnosed late and most commonly affects postmenopausal women between 60 and 70 years, the median age being between 65 years and 67 years (1, 4, 9, 13–17). When compared to women with epithelial serous ovarian carcinomas, women with ovarian carcinosarcoma tend to be of an older age (15, 18–21).

In a study using Surveillance Epidemiology End Result Database from 2000 to 2016, 1193 cases of ovarian carcinosarcoma were reviewed. Ovarian carcinosarcoma was more common in Caucasians, followed by Black women. In comparison to cervical carcinoma, ovarian carcinosarcoma affected more White women and less Black women. However, this could be due to socioeconomic status and cultural differences, apart from genetic factors (22).

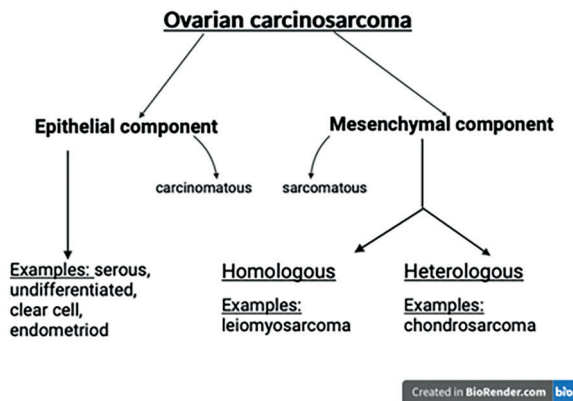
Another study involving 280 non-Hispanic Blacks and 2586 non-Hispanic Whites with ovarian carcinosarcoma, showed that racial differences play a role in characteristics, treatment and survival of ovarian carcinosarcoma, but further research is needed. Low income was an independent prognostic factor but in contrast to uterine carcinosarcoma, race was not an independent prognostic factor (23).

## PATHOPHYSIOLOGY

Typically, the tumour in ovarian carcinosarcoma is large containing substantial areas of necrosis and haemorrhage. The point of origin in the female reproductive tract does not seem to make a difference when it comes to biology and morphology of the tumour (1). The pathophysiology of ovarian carcinosarcoma consists of two phases: epithelial and mesenchymal, both are malignant and high grade (Figure 1) (20, 24, 25). The amount of the two components in a tumour varies between neoplasms. The epithelial part is carcinomatous while the mesenchymal part is sarcomatous. Up to 80% of the epithelial component is high grade serous while in about 20% of cases, it is endometrioid (20). Rarer epithelial components include undifferentiated features and clear cell (26, 27). The sarcomatous part can be homologous shown histologically by the proliferation of spindle cell or undifferentiated round cell and involve leiomyosarcomas and fibrosarcomas. It can also be of a heterologous type such as osteosarcomatous, rhabdomyosarcomas, chondrosarcomatous or liposarcomatous which contain cells which are abnormal to the primary site. The two most common heterologous sarcomatous elements are chondrosarcoma, present in 30% of cases and rhabdomyosarcoma, present in 20% of cases (20). The existence of the heterologous component was shown using immunohistochemistry by analysing various markers such as S100, vimentin, desmin, cytokeratin, epithelial membrane antigen, myogenin, chromogranin and synaptophysin among others. Another significant change is myxoid with hyaline globules (1, 4, 9, 10, 26, 28–33).

More research is needed to know and understand the effect of the heterologous component on prognosis and survival. This is because some researchers propose that if the heterologous component is present, the prognosis is poorer (4, 33, 34). However latest studies report that these histological subgroups are clinically equal (4, 16, 20, 35–37). Overall, prognosis does not seem to significantly depend on the morphology of the subtypes of the tumour. As a result, the 'International Collaboration on Cancer Reporting' recommendation is that although classifying mesenchymal and epithelial subtypes is not easy, taking note of the amount of elements and subtypes of mesenchymal and epithelial components would be helpful to gain more

knowledge about this tumour (24). In the study conducted by Jain et al., when the sarcomatous component is homologous, there is a statistically significant advancement in overall survival and disease-free survival (4). In contrast, in a study conducted in 2020 involving 82 patients, histological subgroups made no difference in survival outcome (38).



**Fig. 1** The two components of ovarian carcinosarcoma. Created with BioRender.com.

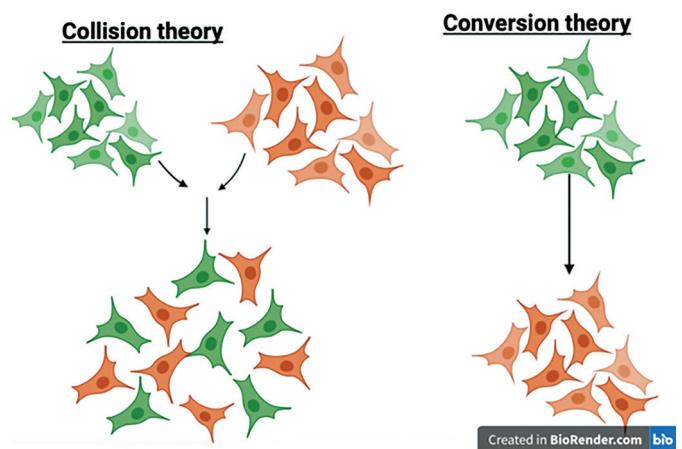
Ovarian carcinosarcoma presents late. As a result, diagnosis is usually made when there is peritoneal spread, at stages III or IV (7, 15). Metastasis is usually to organs within the abdomen such as bladder, omentum, liver and spleen. Distant site metastasis such as to brain, lung and bone is rare (7, 39).

In 90% of cases, there is spread out from the ovary, into the peritoneum. Widespread metastatic disease is present in nearly 75% of patients. Epithelial and sarcomatous cell types are both frequently found in metastatic spread (3). Lymph node metastasis occurs more commonly in ovarian carcinosarcoma rather than in uterine carcinosarcoma. This was established by a research study conducted in 2017, where lymph node metastasis was present in 40% of patients with uterine cancer while 67% of patients with ovarian carcinosarcoma had lymph node metastasis. Lymph node metastasis occurs between 24 and 74% of cases of ovarian carcinosarcoma depending on the stage and is present at the time of diagnosis in more than 50% of patients (40).

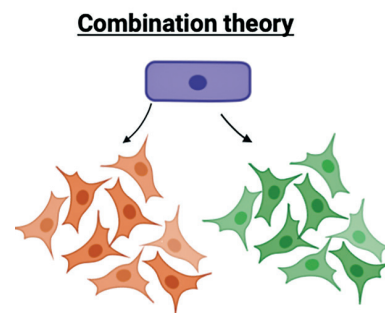
Several theories for the histogenesis of carcinosarcomas are present which gave rise to many debates. Examples of such theories include the collision, conversion and combination theory. The collision and conversion theories are the main accepted theories (Figure 2). The collision theory states that carcinoma and adenosarcoma formed independently and then joined, forming one carcinosarcoma. The conversion theory states that first a carcinoma develops, which later differentiates into sarcoma. The combination theory states that both carcinoma and sarcoma arise from a monoclonal origin. According to Berton et al., the preferred one is the conversion theory. Findings from molecular testing and immunohistochemistry, support the idea that ovarian carcinosarcomas are metaplastic (1, 41). This means that carcinosarcoma cells have the capacity to change to epithelial or mesenchymal component or to both. Furthermore, immunohistochemistry has

shown that epithelial markers are present in the sarcoma part of carcinosarcoma (1, 14, 21, 25). Further studies have shown that the two components are monoclonal and have the same genetic changes, suggesting that even though neoplasms may be separate, most indicate one neoplastic process (1, 14, 21).

Other studies have found a correlation between ovarian carcinosarcoma and serous intraepithelial carcinoma, thus proposing the hypothesis that ovarian carcinosarcoma arises from serous intraepithelial carcinoma of the fallopian tube (42–46). Rewsuwan et al. described the origin of ovarian carcinosarcoma from fallopian tube carcinoma by epithelial mesenchymal transition since carcinosarcoma, teratoma and carcinoma of the fallopian tube coexist (42, 47).



**Fig. 2.1** Diagrammatic representation of Collision and conversion theory. Created with BioRender.com (48).



**Fig. 2.2** Diagrammatic representation of combination theory. Created with BioRender.com.

Molecular markers for epithelial and mesenchymal components have been identified using immunohistochemistry. Epithelial markers include anti-endothelial antibody (anti-EMA) markers and anti-CK monoclonal antibodies while mesenchymal markers include myoglobin, vimentin, smooth muscle actin, desmin and CD10 (15).

One such molecular marker is the overexpression of P53 which is correlated with late stage and poor prognosis in ovarian carcinosarcoma. This was suggested by a case study by Liu et al. where patients with ovarian carcinosarcoma had mutations in the gene for P53 (49). Another study showed that survival might be impacted by overexpression of P53. However, this study was conducted

on a few patients (50). Additional molecular markers expressed are vascular endothelial growth factor (VEGF) and VEGFR-3. In a study, VEGF and VEGFR-3 were found to be associated with poor survival in contrast to another study which showed that when VEGF is expressed, the survival was not significantly different (14, 50).

## CLINICAL FINDINGS

Ovarian carcinosarcoma and other epithelial ovarian cancers have similar clinical signs and symptoms. However, those of OCS have worse consequences (15). Initial signs and symptoms are mostly concerned with the gastrointestinal system such as abdominal pain and abdominal distension (9). Clinical features found commonly in patients with ovarian carcinosarcoma include ascites, pleural effusion, abnormal Papanicolaou test, bowel subobstruction, vaginal bleeding, an irregularly shaped pelvic mass felt during a gynaecological examination, abdominal distension and pelvic pain (3, 9, 51–53). Digestive disorders, vomiting and weight loss may also be present (6, 28, 40). Most patients are asymptomatic when the diagnosis is made (7, 15).

Additionally, on gynaecological ultrasound, a solid pelvic mass can be visible. A common feature of ovarian carcinosarcoma visible on ultrasound is the presence of solid components. In a study containing 91 patients with OCS, the most common finding on ultrasound was a large solid tumour with irregular borders and cystic areas with inhomogeneous echogenicity in the solid parts. However, such a presentation is not diagnostic of OCS as there is significant overlap with other types of ovarian cancers (27, 39, 53). On computed tomography (CT), the mass is also described to be solid with cystic areas with the solid part having a nodular or flocculent shape. Additionally, it can accurately describe the location of the mass, shape and size as well as noting if there is invasion elsewhere and metastasis. CT is the gold standard to confirm the diagnosis. However, staging provided by CT and surgical pathology staging are not the same and peritoneal fluid may hinder visualisation of invasion and metastasis to lymph nodes (53).

All clinical findings are very non-specific, making the diagnosis of OCS more challenging.

## MANAGEMENT

Rarer subtypes of epithelial ovarian cancers such as ovarian carcinosarcoma, have different response to standard approaches. This calls for further research on treatments especially on novel therapies (8).

The ideal treatment for ovarian carcinosarcoma remains undetermined and no consensus agreement has been reached. One reason for this is that most research on ovarian carcinosarcoma is using retrospective reviews rather than clinical trials. The basis for treatment recommendations are retrospective studies. However due to the rarity of this tumour, studies are done using small number of patients. Therefore, although survival is improved

with surgery (54–56), these studies cannot fully state the cause-and-effect correlation between cytoreductive surgery and overall survival. The main treatment for ovarian carcinosarcoma is optimal cytoreductive surgery including bilateral adnexectomy, appendectomy, hysterectomy and omentectomy, with peritoneal biopsies and lymphadenectomy of the pelvic and lumbar-aortic lymph nodes. This needs to be followed by adjuvant chemotherapy even if the tumour is stage I, which is based on platinum usually carboplatin-paclitaxel even though the response rate of carcinosarcoma to chemotherapy is poor (1, 6, 9, 15, 55, 57–60). This is further shown in another study where cytoreductive surgery followed by chemotherapy and targeted therapy is a promising treatment for ovarian carcinosarcoma (9).

One large study was carried out in 2013 involving 47 patients and a study period from 1993 to 2009 in Cleveland, USA. From this study, it was reported that there is a relationship between complete cytoreduction to no gross residual disease and better survival. The goal of the first treatment should be cytoreductive surgery to no gross residual disease. Another finding was that platinum-based therapy may be better than other forms but the ideal adjuvant therapy regimen is not clear. One of the main strengths is that this study is amongst the most current and largest studies on ovarian carcinosarcoma done by one institution which identified prognostic factors which may impact survival. It is important to note that in this study there were some limitations such as the design of the study, small number of patients, many different treatments and other intrinsic limitations (55).

Another study was conducted in 2017 by Yalcin et al. Two important results emerged. Firstly, ovarian carcinosarcoma and high-grade serous carcinoma have similar overall survival and disease-free survival rates when treatment involves cytoreduction and then chemotherapy based on combination of both platinum and taxane. Secondly, one of the independent prognostic factors is platinum resistance in patients with ovarian carcinosarcoma. This study supports the hypothesis that treatment for ovarian carcinosarcoma should be optimal cytoreductive surgery followed by adjuvant chemotherapy based on platinum and taxane. It needs to be noted that this study was conducted using 54 cases and thus more studies with more patients diagnosed with ovarian carcinosarcoma are needed (61).

A larger study performed in 2021 with 82 patients, showed that stages I and II being treated with adjuvant chemotherapy, followed by surgery led to increase in survival rate, further showing the significant role of debulking surgery to no visible residual disease. Nonetheless, it states that ovarian carcinosarcoma has low rate of survival with high relapse risk regardless of stage, patient age and first line therapy (38).

To improve the surgical outcome, three or six cycles of chemotherapy can be administered before the operation. Even though the main treatment is cytoreductive surgery followed by chemotherapy, data are lacking when it comes to support cytoreductive surgery followed by chemotherapy (21, 60). The main aim of cytoreductive surgery is to obtain optimal tumour reduction to no gross residual



disease. However, reaching the stage where gross residual disease is not present, is correlated with a high rate of morbidity after the operation (4, 8, 62, 63). Adjuvant therapy is needed since ovarian carcinosarcoma has a high rate of recurrence. Randomized studies which are specific for ovarian carcinosarcoma adjuvant therapy are absent since this is a rare tumour type (8) and thus no consensus has been reached on using chemotherapy as a first-line treatment (9).

## CURRENT MANAGEMENT

### SURGERY

Surgery for ovarian carcinosarcoma is similar to that of epithelial ovarian cancers and done by gynaecologic oncologists with experience (4, 64, 65). Conservative surgery is never used for ovarian carcinosarcoma. Instead, increasing amount of data demonstrate the value of optimal surgical cytoreduction with bilateral salpingo-oophorectomy, total abdominal hysterectomy, tumour debulking, omentectomy, para-aortic and pelvic lymph node removal and aspiration of abdominal fluid (57). The aim of cytoreduction is to reduce the tumour to an optimal level as survival may be associated with residual disease as will be discussed further on (9). Even though optimal cytoreduction is associated with better survival (13, 33–35, 37), its role has not yet undergone a prospective evaluation. Earlier studies did not evaluate the connection between survival and extent of cytoreductive surgery (4, 17) but later studies show that cytoreductive surgery impacts survival. Small studies done with fewer than 50 participants with the disease, report an improved outcome with optimal debulking surgery. Another larger study with 50 patients having only microscopic disease, reported disease-free survival for these patients. Improved survival for patients with lymphadenopathy as reported by “Surveillance, epidemiology and end results” (SEER) database, suggest the current use of lymph node dissection (1). Nevertheless, at advanced stage, systemic lymphadenectomy is not suggested (66). In a study with 363 patients, conducted by Wang et al., no significant difference for early stage ovarian carcinosarcoma was found between patients who underwent lymph node dissection and those who did not. This shows that in early stage disease, lymph node dissection might not be related to prognosis. Nonetheless, the use of lymph node dissection during the early-stage needs to be studied further (9, 67).

According to European Society of Gynaecological Oncology (ESGO), the surgery of choice for stage I and II are total hysterectomy and bilateral salpingo-oophorectomy, together with the recommendation of bilateral pelvic and para-aortic lymph node dissection. Such surgeries are done using a midline laparotomy approach. However, for stage I, surgery can also be done laparoscopically by an appropriate gynaecological oncologist.

For stages III–IV, surgery is done via a midline laparotomy. The goal of stage III–IV is to completely resect any visible disease. Nonetheless, the presence of metastasis might not be amenable to resection such as parenchymal lung metastasis. Primary surgery is carried out in situations

where the tumour can be debulked to leave no tumour with a low complication rate. If patient is fit for surgery and the tumour is amenable to complete resection, interval debulking surgery is recommended (68).

## ADJUVANT TREATMENT

### 1. For early stage

Adjuvant systemic treatment is taken into consideration because of high recurrence rate, both at local and distant sites. The best adjuvant therapy is still not yet known as many studies have been carried out on a small number of patients (1).

### 2. Radiotherapy

The necessary use of adjuvant radiotherapy remains unknown in spite of the presence of the sarcomatous element (60). Adjuvant radiotherapy is not used since in many cases, the ovarian carcinosarcoma presents late and its use lacks data (14). However, it may lower local recurrences and its effects may be better only in terms of local control (1, 9). The use of radiotherapy in early cases remain undetermined. Radiotherapy might be advantageous for the management of single, stand-alone recurrences in the pelvic region but no studies have yet been done (1, 14). When chemotherapy and radiotherapy are combined, the survival rate may be better, but more studies are needed to determine the role and effect of radiotherapy. A study conducted in 2015 has proved that chemotherapy together with lattice radiation therapy used for the treatment of large tumours greater than 6 cm, was well-tolerated, provided higher local control, reduced the size of the tumour and provided exceptional follow-up results, both clinically and imaged-based, for more than 4 years (9, 69).

### 3. Chemotherapy

The recommended type of chemotherapy, supported by limited data, is one which is platinum-based (70). However, patients with serous carcinoma responded better than with OCS (9, 46). Chemotherapy mainly administered are paclitaxel/ carboplatin, paclitaxel/ ifosfamide and cisplatin/ ifosfamide (9). ESGO recommends adjuvant platinum-based chemotherapy to all patients with stage I and II disease (71).

Ifosfamide and platinum are efficient for the treatment of both endometrial and ovarian carcinosarcomas (55, 72–75). Carboplatin/ paclitaxel has a high response rate to carcinosarcomas, which goes up to 72% and the toxicity is more favoured than ifosfamide or cisplatin (13, 17, 55, 76). Platinum, alkylating agents and anthracyclines combinations can be used for chemotherapy but the toxicity is very high and thus not favoured with the majority of patients who underwent this type of chemotherapy needing to change the treatment (55, 77, 78).

A phase III randomised controlled trial conducted by Powell et al., with 449 patients with uterine carcinosarcoma and 90 ovarian carcinosarcoma patients, recommends paclitaxel and carboplatin chemotherapy as a standard

regimen for uterine carcinosarcoma while paclitaxel and carboplatin should be contemplated for ovarian carcinosarcoma. Strengths of this study include randomization of patients to the paclitaxel and ifosfamide or paclitaxel and carboplatin regimens. In addition, the patients who were included were at different stages of the disease, race and age, and never received chemotherapy and apart from assessing the progression free survival and adverse effects of such therapies, the quality of life and neurotoxicity were also included. One weakness of this study was that the sample size for ovarian carcinosarcoma was small to investigate the effect of such therapies on progression free survival rate. This is justifiable, given the rarity of the tumour. Another weakness was that it did not compare the effect of treating molecular abnormalities such as HER2 overexpression in uterine carcinosarcoma (79).

Based on the 2020 “National Comprehensive Cancer Network Clinical Practice Guidelines in Oncology for Ovarian Cancer,” paclitaxel/carboplatin should be used firstly as chemotherapy (9,80). One study performed was by Loizzi where the median overall survival for cisplatin/etoposide/ifosfamide and taxol/carboplatin groups was similar but, in the cisplatin/etoposide/ifosfamide group, there were more negative effects due to more toxicity that has even resulted in one death (3). Nonetheless, the largest study conducted included 50 patients (1). A study using 136 patients suffering from ovarian carcinosarcoma was conducted by Tate Thigpen et al. In this study these 136 patients were administered cisplatin every 3 weeks up to when high toxicity or disease progression were reached. The overall median survival was found to be 11.7 months (9, 75).

However, it is not known if platinum-based chemotherapy should be given alone or together with paclitaxel or ifosfamide (3). A study involving 29 patients demonstrated that giving cisplatin and ifosfamide instead of paclitaxel and carboplatin, increase overall survival. This result may be due to selection bias and that ifosfamide was given to patients who underwent cytoreduction after an earlier diagnosis (13). Due to these conflicting results, a Cochrane review was done and it showed no evidence to guide decision-making when it comes to adjuvant chemotherapy (8, 81). With regards to advanced stage disease, no significant difference was found using either cisplatin/ifosfamide or paclitaxel/carboplatin.

Another case-control study involving 50 cases of women with advanced carcinosarcoma, demonstrated that the response rates of ovarian carcinosarcoma to platinum and taxane-based chemotherapy used as a first-line, were worse than that of serous epithelial ovarian carcinomas (13). Complete response to second-line chemotherapy was higher in ovarian carcinosarcomas than in uterine carcinosarcoma (70).

A clinical trial, by “Gynecologic Oncology Group” GOG 261, of paclitaxel and carboplatin versus ifosfamide and paclitaxel in women with carcinosarcoma of the ovary, uterus, peritoneum or fallopian tube which is recurrent or persistent carcinosarcoma and stages I-IV, was performed. It proved that paclitaxel and carboplatin had a higher progression free survival (PFS) and thus paclitaxel and carboplatin were not inferior to paclitaxel plus ifosfamide when it comes to survival. Therefore, this supports

paclitaxel and carboplatin used as adjuvant treatment for ovarian carcinosarcoma (8, 66, 82).

Furthermore, no statistical significant difference in survival rate was found in a study involving 22 patients treated with carboplatin and paclitaxel or cisplatin and ifosfamide (83).

However, another study conducted showed that receiving ifosfamide as part of the treatment for ovarian carcinosarcoma improved survival and progression-free interval (13). More research is needed to understand the role of ifosfamide as ifosfamide is associated with toxicity.

There is a trend that platinum-based chemotherapy may be more beneficial. There was no difference in survival using platinum-based chemotherapy in the study conducted by Jernigan et al. However, this result may be due to a small sample size (55). Contrastingly, Chun et al. reported better overall survival and progression free interval when paclitaxel/ platinum-based combinations were used (55, 56). Furthermore, Paulsson et al. showed that improved survival was increased in 57% of 81 patients who received 6 cycles of platinum based chemotherapy (55,84). Recurrence rate was found to be the same in those who received chemotherapy and those patients who did not (21).

The use of adjuvant chemotherapy remains unclear. Controlling cancer-related symptoms should be the goal of treatment after the tumour becomes unresponsive to platinum. The type of chemotherapeutic agent that should be used, should depend on the patient’s toxicity profile and efficacy (14). Treatment for recurrent ovarian carcinosarcoma is not available. Therefore, treatment should then be based on symptoms and reducing morbidity.

## CURRENT DEVELOPMENTS AND FUTURE OPTIONS

### *Neoadjuvant chemotherapy*

It has been reported that neoadjuvant chemotherapy could be used for better results in patients with advanced gynaecological tumour, however this is not specific to ovarian carcinosarcoma, but applies to ovarian cancers in general. More research is needed as only a few patients suffering from ovarian carcinosarcoma of stages IIB and IIIC were studied (4, 85, 86). Additionally, another study stated that when cytoreductive surgery cannot be performed due to high risks or when optimal debulking by cytoreductive surgery cannot be reached, neoadjuvant chemotherapy should be given instead (40, 57).

In a study, eribulin, a new drug targeting microtubules has been investigated for a potential role in targeting ovarian carcinosarcoma using genetically engineered mouse models and patient derived xenografts. Eribulin has an effect on the reversal of epithelial-to-mesenchymal transition. This study has shown that eribulin decreased adhesion, invasion and branching of ovarian carcinosarcoma tumour growth and decrease the expression of HMGA2, N-cadherin and other mesenchymal markers, leading to tumour regression. In fact, tumour cell growth was decreased after just 1 single dose of eribulin. All this points towards the reversal effect of epithelial-mesenchymal transition of eribulin. When compared to platinum-based

chemotherapy, such study showed that anti-microtubule agents such as eribulin had more effect. Eribulin also reduces significantly gene expression of MVA pathway while upregulating genes leading to activation of immune response. This study recommends that early phase clinical trials using eribulin alone or together with immunotherapy would lead to an improvement in management of ovarian carcinosarcoma (87).

### Targeted therapy

Targeted therapy is beneficial as cancerous cells are killed while less healthy cells are targeted than when compared with other treatments (9). The function of targeted therapy is to inhibit specific pathways or molecular changes (10, 15). Even though new targeted therapies are emerging, more studies about genetic and molecular changes in ovarian carcinosarcoma are needed in order to improve targeted therapy for ovarian carcinosarcoma.

In most target therapies, Her2/ neu pathway is targeted (9, 14). Guzzo et al. found that HER2/ neu was expressed in two cell lines of ovarian carcinosarcoma. Then, using fluorescent in situ hybridization technique, it was found that c-erbB2 gene was amplified (9, 88). Targeted therapies are being studied on mouse models. One such targeted therapy is Neratibib whose effect is stopping tumour growth and increased survival rate in the mouse. Another such targeted therapy is T-DM1 which also targets HER2/neu pathway (14). Additionally, SYD985 is another example being studied. It is based on duocarmycin and its effect is to kill tumour cells with HER2/neu 0/1 mixed with HER2/neu 3+ cells (9, 15, 89). Solitomab, a bispecific antibody construct of CD3 which is an epithelial cell adhesion molecule, has been shown to increase CD4+ and CD8+ T cells *ex vivo* (9). Aflibercept which is a VEGF Trap, had very little effect on patients diagnosed with ovarian carcinosarcoma (14).

Presently, there is insufficient evidence to show if surgery alone or surgery with radiotherapy or chemotherapy, or both, is better or worse to increase survival rate and enhance the quality of life (81). Cytoreductive surgery may only eliminate local lesions. Apart from weakening the patient and the immune system, radiotherapy and chemotherapy do not remove all cancer cells. Likewise, targeted therapy would solely kill cancer cells with specific molecular targets, while those cancer cells without such molecular targets, would not be killed (9).

## PROGNOSIS

Ovarian carcinosarcomas has a poor prognosis especially when the tumour is still localised. The later the diagnosis, the worse is the prognosis (52). This is shown as the prognosis was better in patients younger than 50 years than in patients who were older (11). Contrastingly, in one study, the prognosis was bad even though it was an early stage disease. This may be due to recurrence which occurred in early stage (70). Prognosis is increased when the residual tumour burden after cytoreductive surgery is less than 1% (9, 33). The median survival rate is between 7 to 10 months,

which is inferior to serous tumours. (18, 90) In another case series, the median survival rate is of 24 months (54) and 21 months after a median follow-up of 28 months (13). Most patients die after 2 years of initial diagnosis (9, 91, 92). When compared with uterine carcinosarcoma and epithelial ovarian cancers, the prognosis for ovarian carcinosarcoma is worse with a higher probability of death (9, 14, 28, 92).

Ovarian carcinosarcoma also present late, at an advanced stage. The stage of ovarian carcinosarcoma is unknown in more women than those serous tumour (18). Moreover, the recurrence rate of ovarian carcinosarcoma is high even within a year of treatment (9, 13, 91, 92). In a study conducted involving 31 patients, 16 of these patients had a median recurrence time of 12 months and after a year, 30% died due to the disease. In this specific study, variables studied were age, institution, histology, residual disease, type of adjuvant therapy and stage. Of these, neither age, histology nor institution seem to affect survival progression-free interval. The stage of the disease influences the progression-free interval as after 2 years, 40% of patients at an advanced stage stayed disease-free while 70% of patients at early stage remain disease-free (13). In fact, many other studies show that the most important prognostic factor is clinical stage (14, 35, 93).

Contrastingly, in the study conducted by Harris et al., there was no significant difference in overall survival rate nor median progression-free interval in early stage when compared with advanced stage (4, 35). In the study conducted by Jian et al., the overall survival and disease-free survival rates were better, but the result for disease free survival was not significant whereas the result for OS was only borderline significant (4). Factors which affect prognosis may include FIGO stage, complete cytoreduction, overexpression of Ki-67 which is a nuclear protein related to cell growth, grade, VEGF expression mutation in P53 gene, presence of residual disease after treatment and others. However, no conclusions can be drawn due to lack of data (1, 9, 36, 50, 84, 94). Research is inconsistent when it comes to whether age and histological type are prognostic factors. Studies conducted by Rutledge and then by Jain, show that age is not a significant prognostic factor (4, 13, 21, 28). However, other researchers have shown that advanced age is a prognostic factor (6, 14, 95, 96). Abdeddine et al. state that histological type is not a prognostic factor (52). Similarly, a study conducted by Yalcin et al. states that histological type does not influence survival when treatment involves optimal cytoreduction and then platinum and taxane based adjuvant chemotherapy (61). Another study conducted by Barnholtz-Sloan found no significant differences in survival when comparing early stage ovarian carcinosarcoma with ovarian serous tumours (61, 92). On the other hand, others reported that the histological type of the tumour is an independent prognostic factor which effects OS. Rauh Hain et al. reported that the histological type of ovarian carcinosarcoma is linked to decreased OS (54, 59, 61). Additionally, George et al. who studied ovarian carcinosarcoma from 1988 to 2007 found that 72% of women diagnosed with ovarian carcinosarcoma had a higher chance to die when compared to patients having high grade serous carcinoma (2, 61). The outcome



is better with cytoreductive surgery and adjuvant chemotherapy which involves ifosfamide (13).

When patients with uterine carcinosarcoma and ovarian carcinosarcoma were compared, the 5-year survival was better in patients with uterine carcinosarcoma. In fact, the results were 54% for OCS and 56% for uterine carcinosarcoma (8, 97). The survival rate is lower than that of serous tumours for all stages of the disease. For example, for ovarian carcinosarcoma stage 1, the survival rate was 65% but that of serous tumour was 81% (14). The survival rate is not significantly affected by the stage present at initial diagnosis, and it is not affected whether the ovarian mass is bilateral or unilateral (21). Survival rate has been shown not to depend on ethnicity, age at diagnosis and tobacco status (21). More importantly, the survival rate depends on residual disease. Residual disease in patients with stage IIIC disease was linked with a lower survival rate (13). The median OS rate is higher in patients without any visible tumour residue compared with patients who had residual tumour even when the residual tumour was less than or equal to 1 cm (9, 54, 98). Additionally, the OS time was higher when the residual lesions were less than 2 cm after initial surgery, when compared to patients whose residual tumour was greater than 2 cm. Hence, prognosis is better with cytoreductive surgery with less than or equal to 1 cm of residual tumour (9, 16, 95). As reported by Loizzi et al., Muntz et al. and Brown et al., but opposed by Barakat et al., the survival rate is better with optimal debulking in contrast to sub optimally debulking (3, 16, 37, 93). Rauh Hain et al. report that OS is better with microscopic residual disease (54, 55).

As shown by the study conducted by Hollis et al. in 2021, having no visible residual disease after optimal debulking surgery, early stages and first line therapy are independently linked with a better survival rate while age and histological sub type do not seem to be linked with overall survival (38).

The level of CA125 pre-op might be a prognostic factor. Jain et al. (4) reported in a study that CA125 level was higher than normal in 85% of patients with ovarian carcinosarcoma. A similar result was published by Sood et al. where CA125 level was elevated in 90% of OCS cases (33). A similar percentage was reported in the study conducted by Jain where the level of CA125 was higher preoperatively in 85% of cases (4). In a study conducted by Ureyen et al., patients with uterine carcinosarcoma had a median pre-operative CA125 level of 50 U/ml while patients with OCS had a pre-operative level of 252 U/ml. This shows that the level of CA125 is higher in ovarian carcinosarcoma than that in UCS (40). If the CA125 level preoperatively is higher than 75 U/ml, there is high chance that the outcome will be poor. A lower CA125 level, is linked with a better prognosis (5, 9, 15). On the other hand, in the case reported by Priyadarshini et al., a 65-year-old patient was reported to have increased level of CA125 above 75 U/ml preoperatively, the value was 102 U/ml but had a long-term survival (15). CA125 may be a marker to guide treatment but this is still uncertain (52, 99, 100). However, survival rate is not dependent on CA125 positive or negative, neither on whether the sarcomatous component is heterologous or homologous (3). It has been shown that ovarian

carcinosarcoma containing parts of serous epithelium has a lower survival rate than epithelial components which do not have serous parts (3). Some limitations which need to be acknowledged are the lack of availability of centralized pathology review, lack of data on residual disease as the survival rate is dependent on the residual disease (8), lack of data when it comes to the type of chemotherapy used as treatment and recurrence pattern, and the individual's and physician preferences that undoubtedly affected treatment allocation were not known (18).

## FUTURE DIRECTIONS

More studies are needed on ovarian carcinosarcoma to improve prognosis and management and overall survival for the patients involved. There is a lack of data when it comes to molecular and genetic changes in ovarian carcinosarcomas. In fact, the data available is only based on a few cases. High resolution single cell sequencing can be used to study molecular characteristics giving rise to histological changes observed (101). Genetic and molecular studies are needed to establish pathways and subtypes involved. Genetic studies may include expression profiling and identifying target genes while molecular studies involve genomic, transcriptomic and proteomic studies. For example, molecular studies to target HER2 and immunosuppressive molecules (38). Research into the role of microRNA may lead to a therapeutic use (102). More research needs to be done to determine what are the prognostic factors with certainty. These studies can be done by trials specific to ovarian carcinosarcoma involving large group of patients and by working together internationally (1). Additionally, mouse models and xenografts from mouse and even from patients, can be used for such studies. Xenograft models can be useful to study growth of tumour such as by injecting human ovarian carcinosarcoma cells in live mice, study metastases, effect of individual genes by implanting human genes in mice as well as response to treatment. Patient derived xenografts can also be used to study genetics involved and treatment response. Studies on genetically engineered mouse models are able to give information on the developmental process of ovarian carcinosarcoma (103).

Additionally, more research is required to improve treatment paradigms (1, 8, 38). Moreover, research is needed when it comes to treatment so as to determine the use of different types of chemotherapy as adjuvant therapy especially with regards to ifosfamide (18). There needs to be more progress to find novel therapy for better outcome (8). By introducing a national registry, trials could be done with more patients with ovarian carcinosarcoma making the study more effective.

## CONCLUSION

Ovarian carcinosarcoma is one rare type of cancer affecting the ovary. Apart from being an uncommon cancer, this cancer is also an aggressive one. Diagnosis is late, and in most cases metastatic disease is already present on



diagnosis. This partly explains the poor prognosis associated with this type of cancer. Since it is a rare type, trials that have been carried out are few and therefore treatment is mainly based on retrospective studies. As discussed above, more studies on this type of ovarian cancer need to be conducted.

Optimal debulking surgery seems to be important for a better outcome and rate of survival, together with adjuvant platinum-based chemotherapy. However, the ideal adjuvant chemotherapy is not yet known. Future efforts are needed to understand this tumour better which help with effective management and increase overall survival.

## REFERENCES

- Berton-Rigaud D, Devouassoux-Shisheboran M, Ledermann JA, et al. Gynecologic cancer intergroup (GCG) consensus review for uterine and ovarian carcinosarcoma. *Int J Gynecol Cancer* 2014; 24(9 Suppl 3): S55-60.
- George EM, Herzog TJ, Neugut AI, et al. Carcinosarcoma of the ovary: Natural history, patterns of treatment, and outcome. *Gynecol Oncol* 2013; 131(1): 42-5.
- Loizzi V, Cormio G, Camporeale A, et al. Carcinosarcoma of the ovary: Analysis of 13 cases and review of the literature. *Oncology* 2011; 80(1-2): 102-6.
- Jain V, Pundir S, Sekhon R, Mishra A, et al. Carcinosarcoma of the Ovary: A Single-Institute Experience with Surgical Cytoreduction and Platinum-Based Chemotherapy. *J Gynecol Surg* 2019; 35(4): 224-31.
- Cantrell LA, van Le L. Carcinosarcoma of the ovary a review. *Obstet Gynecol Surv* 2009; 64(10): 673-80; quiz 697.
- Limaïem F, Halouani A, Saffar K, Bouraoui S. A rare and distinct bilateral ovarian tumor: Carcinosarcoma. *Clin Case Rep* 2021; 9(12): e05160.
- Kozłowski M, Nowak K, Kordek A, Cymbaluk-Płoska A. Therapeutic management of rare primary ovarian neoplasms: Carcinosarcoma, leiomyosarcoma, melanoma and carcinosarcoma. *Int J Environ Res Public Health* 2021; 18(15): 7819.
- Cobb LP, Gershenson DM. Treatment of Rare Epithelial Ovarian Tumors. *Hematol Oncol Clin North Am* 2018; 32(6): 1011-1024.
- Fu J. Management of a rare ovarian carcinosarcoma: A case report and literature review. *Exp Ther Med* 2022; 24(3), <https://doi.org/10.3892/etm.2022.11520>.
- del Carmen MG, Birrer M, Schorge JO. Carcinosarcoma of the ovary: A review of the literature. *Gynecol Oncol* 2012; 125(1): 271-7.
- Salman L, Brudner Y, Silverman BG, Hallak M, Bruchim I. Increased incidence with improved survival of gynecologic carcinosarcoma: A population-based study. *Eur J Obstet Gynecol Reprod Biol* 2021; 266: 106-10.
- Kadan Y, Fishman A, Helpman L. Ethnic Disparities for Gynecologic Cancers in Israel. *J Racial Ethn Health Disparities* 2020; 7(3): 421-7.
- Rutledge TL, Gold MA, McMeekin DS, et al. Carcinosarcoma of the ovary - A case series. *Gynecol Oncol* 2006; 100(1): 128-32.
- Rauh-Hain JA, Birrer M, del Carmen MG. "Carcinosarcoma of the ovary, fallopian tube, and peritoneum: Prognostic factors and treatment modalities." *Gynecol Oncol* 2016; 142(2): 248-54.
- Priyadarshini P, Majumdar S das, Parida D. Carcinosarcoma of ovary with long-term overall survival. *Oncol J India* 2019; 3(2): 41.
- Brown E, Stewart M, Rye T, et al. Carcinosarcoma of the ovary: 19 years of prospective data from a single center. *Cancer* 2004; 100(10): 2148-53.
- Leiser AL, Chi DS, Ishill NM, Tew WP. Carcinosarcoma of the ovary treated with platinum and taxane: the memorial Sloan-Kettering Cancer Center experience. *Gynecol Oncol* 2007;105(3): 657-61.
- George EM, Herzog TJ, Neugut, et al. Carcinosarcoma of the ovary: Natural history, patterns of treatment, and outcome. *Gynecol Oncol* 2013; 131(1): 42-5.
- del Carmen MG, Young RH, Schorge JO, Birrer MJ, editors. *Uncommon Gynecologic Cancers*, Wiley 2014.
- Hollis RL. Molecular characteristics and clinical behaviour of epithelial ovarian cancers. Vol. 555, *Cancer Lett* 2023; 555: 216057.
- Nizam A, Bustamante B, Shan W, et al. Overall survival and adjuvant therapy in women with ovarian carcinosarcoma: A single-institution experience. *Diagnostics (Basel)* 2019; 9(4): 200.
- Lee JW, Ouh YT, Chang HK, et al. Trends in Gynecologic Carcinosarcoma Based on Analysis of the Surveillance Epidemiology End Result (SEER) Database. *J Clin Med* 2023; 12(3): 1188.
- Rojas C, Tian C, Powell MA, et al. Racial disparities in uterine and ovarian carcinosarcoma: A population-based analysis of treatment and survival. *Gynecol Oncol* 2020;157(1): 67-77.
- Glenn McCluggage W, Judge MJ, Clarke BA, et al. Data set for reporting of ovary, fallopian tube and primary peritoneal carcinoma: Recommendations from the International Collaboration on Cancer Reporting (ICCR). *Mod Pathol* 2015; 28(8): 1101-22.
- Boussios S, Karathanasi A, Zakythinakis-Kyriakou N, et al. Ovarian carcinosarcoma: Current developments and future perspectives. *Crit Rev Oncol Hematol* 2019; 134: 46-55.
- George E, Manivel JC, Dehner LP, Wick MR. Malignant mixed müllerian tumors: an immunohistochemical study of 47 cases, with histogenetic considerations and clinical correlation. *Hum Pathol* 1991; 22(3): 215-23.
- Nayak R, Sahoo T. Carcinosarcoma of Ovary, it's Histopathological, Management and Prognostic Analysis with Review of Literature. *J Cancer Tumor Int* 2016; 3(2): 1-10.
- el Hilali Fouzia, Lemrabott E, Errarhay S, Mamouni N, Bouchikhi C, Banani A. Ovarian Carcinosarcoma. *Sch J Med Case Rep* 2021; 9(4): 421-3.
- Athavale R, Thomakos N, Godfrey K, et al. The effect of epithelial and stromal tumor components on FIGO stages III and IV ovarian carcinosarcomas treated with primary surgery and chemotherapy. *Int J Gynecol Cancer* 2007; 17(5): 1025-30.
- McCluggage WG, Lioe TF, McClelland HR, Lamki H. Rhabdomyosarcoma of the uterus: Report of two cases, including one of the spindle cell variant. *Int J Gynecol Cancer* 2002; 12(1): 128-32.
- Trento M, Munari G, Carraro V, et al. Mutational and Immunophenotypic Profiling of a Series of 8 Tubo-ovarian Carcinosarcomas Revealed a Monoclonal Origin of the Disease. *Int J Gynecol Pathol* 2020; 39(4): 305-12.
- Pankaj S, Nazneen S, Kumari A, Kumari S, Choudhary V, Roy VK. A Rare Tumor of the Ovary: Carcinosarcoma Report and Review of Literature. *J Obstet Gynaecol India* 2016; 66(Suppl 2): 648-50.
- Sood AK, Sorosky JI, Gelder MS, et al. Primary ovarian sarcoma: analysis of prognostic variables and the role of surgical cytoreduction. *Cancer* 1998; 82(9): 1731-7.
- Mano MS, Rosa DD, Azambuja E, et al. Current management of ovarian carcinosarcoma. *Int J Gynecol Cancer* 2007; 17(2): 316-24.
- Harris MA, Delap LM, Sengupta PS, et al. Carcinosarcoma of the ovary. *Br J Cancer* 2003; 88(5): 654-7.
- Ariyoshi K, Kawauuchi S, Kaku T, Nakano H, Tsuneyoshi M. Prognostic factors in ovarian carcinosarcoma: a clinicopathological and immunohistochemical analysis of 23 cases. *Histopathology* 2000; 37(5): 427-36.
- Muntz HG, Jones MA, Goff BA, et al. Malignant mixed müllerian tumors of the ovary. Experience with surgical cytoreduction and combination chemotherapy. *Cancer* 1995; 76(7): 1209-13.
- Hollis RL, Croy J, Churchman M, et al. Ovarian carcinosarcoma is a distinct form of ovarian cancer with poorer survival compared to tubo-ovarian high-grade serous carcinoma. *Br J Cancer* 2022; 127(6): 1034-1042.
- Ciccarone F, Biscione A, Moro F, et al. Imaging in gynecological disease (23): clinical and ultrasound characteristics of ovarian carcinosarcoma. *Ultrasound Obstet Gynecol* 2022; 59(2): 241-247.
- Ureyen I, Karalok A, Cirik DA, et al. Uterine and Ovarian Carcinosarcomas: Do They Behave Similarly? *J Obstet Gynaecol Can* 2017; 39(7): 559-563.
- Niwa K, Mori S, Kuwabara K, et al. Primary Ovarian Carcinosarcoma: Cytological, Pathological, Immunocytochemical, and Immunohistochemical Features. *OJ Pathology* 2021; 11(01): 22-31.
- Guo S, Zhang X, Tang Q, Zhou M, Jiang D, Yu E. Genetic Analysis and Combined Therapy of Surgery and Chemotherapy for the Progression-Free Survival of a Patient with Ovarian Carcinosarcoma: A Case Report and Literature Review. *Onco Targets Ther* 2022; 15: 717-25.
- Mikami Y. [Paradigm Shift in Ovarian Tumor Pathology from the View of Genomic Abnormalities]. *Gan To Kagaku Ryoho* 2016; 43(3): 286-9.
- Terada KY, Ahn HJ, Kessel B. Differences in risk for type 1 and type 2 ovarian cancer in a large cancer screening trial. *J Gynecol Oncol* 2016; 27(3): e25.
- Weinberger V, Bednarikova M, Cibula D, Zikan M. Serous tubal intraepithelial carcinoma (STIC) - clinical impact and management. *Expert Rev Anticancer Ther* 2016; 16(12): 1311-21.
- Seidman JD. Serous Tubal Intraepithelial Carcinoma Localizes to the Tubal-peritoneal Junction. *Int J Gynecol Pathol* 2015; 34(2): 112-20.

47. Rewsuwan S, Satabongkoch N, Suprasert P, Khunamornpong S. Ovarian Carcinosarcoma and Its Association with Mature Cystic Teratoma and Primary Tubal Carcinoma. *Case Rep Pathol* 2016; 2016: 2605045.
48. Kostov S, Kornovski Y, Ivanova Y, et al. Ovarian carcinosarcoma with retroperitoneal para-aortic lymph node dissemination followed by an unusual postoperative complication: A case report with a brief literature review. *Diagnostics (Basel)* 2020; 10(12): 1073.
49. Liu FS, Kohler MF, Marks JR, Bast RC, Boyd J, Berchuck A. Mutation and overexpression of the p53 tumor suppressor gene frequently occurs in uterine and ovarian sarcomas. *Obstet Gynecol* 1994; 83(1): 118–24.
50. Zorzou MP, Markaki S, Rodolakis A, et al. Clinicopathological features of ovarian carcinosarcomas: a single institution experience. *Gynecol Oncol* 2005; 96(1): 136–42.
51. Berton-Rigaud D, Devouassoux-Shisheboran M, Ledermann JA, Leitao MM, Powell MA, Poveda A, et al. Gynecologic cancer intergroup (GCG) consensus review for uterine and ovarian carcinosarcoma. *Int J Gynecol Cancer* 2014; 24(9 Suppl 3): S55–60.
52. Abdeddine F, Meddah J, el Youssfi M, Benyahia M, Bargach S. Ovarian Carcinosarcoma: A case report and review of literature. *Int J Innov Appl Stud* 2019; 27(3): 793–796.
53. Zheng J, Tang C, Liu P, Hao H. Carcinosarcoma of the ovary: a case report and literature review. *Front Oncol* 2023; 13: 1278300.
54. Rauh-Hain JA, Growdon WB, Rodriguez N, et al. Carcinosarcoma of the ovary: A case-control study. *Gynecol Oncol* 2011; 121(3): 477–81.
55. Jernigan AM, Fader AN, Nutter B, Rose P, Tseng JH, Escobar PF. Ovarian Carcinosarcoma: Effects of Cytoreductive Status and Platinum-Based Chemotherapy on Survival. *Obstet Gynecol Int* 2013; 2013: 490508.
56. Chun KC, Kim JJ, Kim DY, et al. Optimal debulking surgery followed by paclitaxel/platinum chemotherapy is very effective in treating ovarian carcinosarcomas: a single center experience. *Gynecol Obstet Invest* 2011; 72(3): 208–14.
57. Raji R, Guzzo F, Carrara L, et al. Uterine and ovarian carcinosarcomas overexpressing Trop-2 are sensitive to hRS7, a humanized anti-Trop-2 antibody. *J Exp Clin Cancer Res* 2011; 30: 106.
58. Zhu J, Wen H, Ju X, Bi R, Zuo W, Wu X. Clinical Significance of Programmed Death Ligand-1 and Intra-Tumoral CD8+ T Lymphocytes in Ovarian Carcinosarcoma. *PLoS One*. 2017; 12(1): e0170879.
59. Rauh-Hain JA, Gonzalez R, Bregar AJ, et al. Patterns of care, predictors and outcomes of chemotherapy for ovarian carcinosarcoma: A National Cancer Database analysis. *Gynecol Oncol* 2016; 142(1): 38–43.
60. Makris GM, Siristatidis C, Battista, Chrelias C, Ovarian carcinosarcoma: a case report, diagnosis, treatment and literature review. *Hippokratia* 2015; 19(3): 256–259.
61. Yalcin I, Meydanli MM, Turan AT, et al. Carcinosarcoma of the ovary compared to ovarian high-grade serous carcinoma: impact of optimal cytoreduction and standard adjuvant treatment. *Int J Clin Oncol* 2018; 23(2): 329–37.
62. Bookman MA, Brady MF, McGuire WP, et al. Evaluation of new platinum-based treatment regimens in advanced-stage ovarian cancer: a Phase III Trial of the Gynecologic Cancer Intergroup. *J Clin Oncol* 2009; 27(9): 1419–25.
63. Chi DS, Zivanovic O, Levinson KL, et al. The incidence of major complications after the performance of extensive upper abdominal surgical procedures during primary cytoreduction of advanced ovarian, tubal, and peritoneal carcinomas. *Gynecol Oncol* 2010; 119(1): 38–42.
64. Engelen MJA, Kos HE, Willemse PHB, et al. Surgery by consultant gynecologic oncologists improves survival in patients with ovarian carcinoma. *Cancer* 2006; 106(3): 589–98.
65. Earle CC, Schrag D, Neville BA, et al. Effect of surgeon specialty on processes of care and outcomes for ovarian cancer patients. *J Natl Cancer Inst* 2006; 98(3): 172–80.
66. Debuquoy C, Romeo C, Vanacker H, Ray-Coquard I. Rare ovarian tumors: An update on diagnosis and treatment. *Int J Gynecol Cancer* 2020; 30(6): 879–87.
67. Wang WP, Li N, Zhang YY, et al. Prognostic significance of lymph node metastasis and lymphadenectomy in early-stage ovarian carcinosarcoma. *Cancer Manag Res* 2018; 10: 1959–68.
68. Querleu D, Planchamp F, Chiva L, et al. European society of Gynaecological Oncology (ESGO) guidelines for ovarian cancer surgery. *Int J Gynecol Cancer* 2017; 27(7): 1534–42.
69. Blanco Suarez JM, Amendola BE, Perez N, Amendola M, Wu X. The Use of Lattice Radiation Therapy (LRT) in the Treatment of Bulky Tumors: A Case Report of a Large Metastatic Mixed Mullerian Ovarian Tumor. *Cureus* 2015; 7(11): e389.
70. Ebata T, Yonemori K, Nishikawa T, et al. Treatment Outcome of Second-Line Chemotherapy for Gynecologic Carcinosarcoma. *Oncology (Switzerland)* 2020; 98(10): 699–705.
71. Ledermann JA, Matias-Guiu X, Amant F, et al. ESGO-ESMO-ESP consensus conference recommendations on ovarian cancer: pathology and molecular biology and early, advanced and recurrent disease. *Ann Oncol* 2024; 35(3): 248–66.
72. Sutton GP, Blessing JA, Rosenshein N, Photopulos G, DiSaia PJ. Phase II trial of ifosfamide and mesna in mixed mesodermal tumors of the uterus (a Gynecologic Oncology Group study). *Am J Obstet Gynecol* 1989; 161(2): 309–12.
73. Thigpen JT, Blessing JA, Beecham J, Homesley H, Yordan E. Phase II trial of cisplatin as first-line chemotherapy in patients with advanced or recurrent uterine sarcomas: a Gynecologic Oncology Group study. *J Clin Oncol* 1991; 9(11): 1962–6.
74. Gershenson DM, Kavanagh JJ, Copeland LJ, Edwards CL, Stringer CA, Wharton JT. Cisplatin therapy for disseminated mixed mesodermal sarcoma of the uterus. *J Clin Oncol* 1987; 5(4): 618–21.
75. Tatethigpen J, Blessing J, Degeest K, Look K, Homesley H. Cisplatin as initial chemotherapy in ovarian carcinosarcomas: a Gynecologic Oncology Group study. *Gynecol Oncol* 2004; 93(2): 336–9.
76. Cicin I, Saip P, Eralp Y, et al. Ovarian carcinosarcomas: clinicopathological prognostic factors and evaluation of chemotherapy regimens containing platinum. *Gynecol Oncol* 2008; 108(1): 136–40.
77. Signorelli M, Chiappa V, Minig L, et al. Platinum, anthracycline, and alkylating agent-based chemotherapy for ovarian carcinosarcoma. *Int J Gynecol Cancer* 2009; 19(6): 1142–6.
78. van Rijswijk REN, Vermorken JB, Reed N, et al. Cisplatin, doxorubicin and ifosfamide in carcinosarcoma of the female genital tract. A phase II study of the European Organization for Research and Treatment of Cancer Gynaecological Cancer Group (EORTC 55923). *Eur J Cancer* 2003; 39(4): 481–7.
79. Powell MA, Filiaci VL, Martee, et al. Randomized Phase III Trial of Paclitaxel and Carboplatin Versus Paclitaxel and Ifosfamide in Patients with Carcinosarcoma of the Uterus or Ovary: An NRG Oncology Trial. *J Clin Oncol* 2022; 40: 968–77.
80. Armstrong DK, Alvarez RD, Bakkum-Gamez JN, et al. Ovarian Cancer, Version 2.2020, NCCN Clinical Practice Guidelines in Oncology. *J Natl Compr Canc Netw* 2021; 19(2): 191–226.
81. Shylasree TS, Bryant A, Athavale R. Chemotherapy and/or radiotherapy in combination with surgery for ovarian carcinosarcoma. *Cochrane Database Syst Rev* 2013; 2020(3).
82. Powell MA, Filiaci VL, Hensley ML, et al. A randomized phase 3 trial of paclitaxel (P) plus carboplatin (C) versus paclitaxel plus ifosfamide (I) in chemotherapy-naïve patients with stage I–IV, persistent or recurrent carcinosarcoma of the uterus or ovary: An NRG Oncology trial. *J Clin Oncol* 2019; 37(15\_suppl): 5500–5500.
83. Silasi Da, Illuzzi JI, Kelly Mg, et al. Carcinosarcoma of the ovary. *Int J Gynecol Cancer* 2008; 18(1): 22–9.
84. Paulsson G, Andersson S, Sorbe B. A population-based series of ovarian carcinosarcomas with long-term follow-up. *Anticancer Res* 2013; 33(3): 1003–8.
85. Takami M, Idei T, Nakayama Y, et al. [A case of advanced ovarian carcinosarcoma that responded remarkably to neoadjuvant chemotherapy of combined CPT-11 and CDDP]. *Gan To Kagaku Ryoho* 2002; 29(2): 305–8.
86. Okazawa M, Masuhara K, Miyoshi A, et al. A rare case of ovarian carcinosarcoma successfully treated with the neoadjuvant chemotherapy of paclitaxel and ifosfamide. *J Obstet Gynaecol* 2011; 31(3): 274–5.
87. Ho GY, Kyran EL, Bedo J, et al. Epithelial-to-Mesenchymal Transition Supports Ovarian Carcinosarcoma Tumorigenesis and Confers Sensitivity to Microtubule Targeting with Eribulin. *Cancer Res*. 2022; 82(23): 4457–73.
88. Guzzo F, Bellone S, Buza N, et al. HER2/neu as a potential target for immunotherapy in gynecologic carcinosarcomas. *Int J Gynecol Pathol* 2012; 31(3): 211–21.
89. Menderes G, Bonazzoli E, Bellone S, et al. SYD985, a Novel Duocarmycin-Based HER2-Targeting Antibody-Drug Conjugate, Shows Antitumor Activity in Uterine and Ovarian Carcinosarcoma with HER2/Neu Expression. *Clin Cancer Res* 2017; 23(19): 5836–45.
90. Rutledge TL, Gold MA, McMeekin DS, et al. Carcinosarcoma of the ovary – a case series. *Gynecol Oncol* 2006; 100(1): 128–32.
91. Duska LR, Garrett A, Eltabbakh GH, Oliva E, Penson R, Fuller AF. Paclitaxel and platinum chemotherapy for malignant mixed müllerian tumors of the ovary. *Gynecol Oncol* 2002; 85(3): 459–63.
92. Barnholtz-Sloan JS, Morris R, Malone JM, Munkarah AR. Survival of women diagnosed with malignant, mixed müllerian tumors of the ovary (OMMMT). *Gynecol Oncol* 2004; 93(2): 506–12.
93. Barakat RR, Rubin SC, Wong G, Saigo PE, Markman M, Hoskins WJ. Mixed mesodermal tumor of the ovary: analysis of prognostic factors in 31 cases. *Obstet Gynecol* 1992; 80(4): 660–4.

94. Boussios S, Karathanasi A, Zakyntinakis-Kyriakou N, et al. Ovarian carcinosarcoma: Current developments and future perspectives. *Crit Rev Oncol Hematol* 2019; 134: 46-55.
95. del Carmen MG, Birrer M, Schorge JO. Carcinosarcoma of the ovary: A review of the literature. *Gynecol Oncol* 2012; 125(1): 271-7.
96. Inthasorn P, Beale P, Dalrymple C, Carter J. Malignant mixed müllerian tumour of the ovary: prognostic factor and response of adjuvant platinum-based chemotherapy. *Aust N Z J Obstet Gynaecol* 2003; 43(1): 61-4.
97. Rauh-Hain JA, Diver EJ, Clemmer JT, et al. Carcinosarcoma of the ovary compared to papillary serous ovarian carcinoma: a SEER analysis. *Gynecol Oncol* 2013; 131(1): 46-51.
98. Doo DW, Erickson BK, Arend RC, Conner MG, Huh WK, Leath CA. Radical surgical cytoreduction in the treatment of ovarian carcinosarcoma. *Gynecol Oncol* 2014; 133(2): 234-7.
99. Brown E, Stewart M, Rye T, et al. Carcinosarcoma of the ovary. *Cancer* 2004; 100(10): 2148-53.
100. Amant F, Vloeberghs V, Woestenborghs H, Moerman P, Vergote I. Transition of epithelial toward mesenchymal differentiation during ovarian carcinosarcoma tumorigenesis. *Gynecol Oncol* 2003; 90(2): 372-7.
101. Yaw Ho G, Kyran EL, Bedo J, et al. Ovarian carcinosarcoma genomics and pre-clinical models highlight the N-MYC 1 pathway as a key driver and susceptibility to EMT-targeting therapy. *bioRxiv*.
102. Ismail A, Abulsoud AI, Fathi D, et al. The role of miRNAs in ovarian cancer pathogenesis and therapeutic resistance - A focus on signaling pathways interplay. *Pathol Res Pract* 2022; 240: 154222.
103. Bobbs AS, Cole JM, Dahl KDC. Emerging and Evolving Ovarian Cancer Animal Models. *Cancer Growth Metastasis* 2015; 8(Suppl 1): 29-36.