

# Sodium-Hyaluronate Cystic-like Lesion in the Anterior Chamber Following Cataract Surgery: A Case Report

---

Christina Mitsi<sup>1,\*</sup>, Minas Bakirtzis<sup>1</sup>, Eirini-Kanella Panagiotopoulou<sup>1</sup>, Georgios Labiris<sup>1</sup>

## ABSTRACT

This is a case report describing the uncommon finding of a cystic-like lesion and its management in the anterior chamber of a male patient after cataract surgery.

## KEYWORDS

anterior chamber cyst; free-floating cystic lesion; cataract surgery

## AUTHOR AFFILIATIONS

<sup>1</sup> Department of Ophthalmology, University Hospital of Alexandroupolis, 68100 Dragana, Alexandroupolis, Greece

\* Corresponding author: Department of Ophthalmology, University Hospital of Alexandroupolis, 68100 Dragana, Alexandroupolis, Greece; e-mail: mitsi.christ@gmail.com

Received: 20 June 2023

Accepted: 12 September 2023

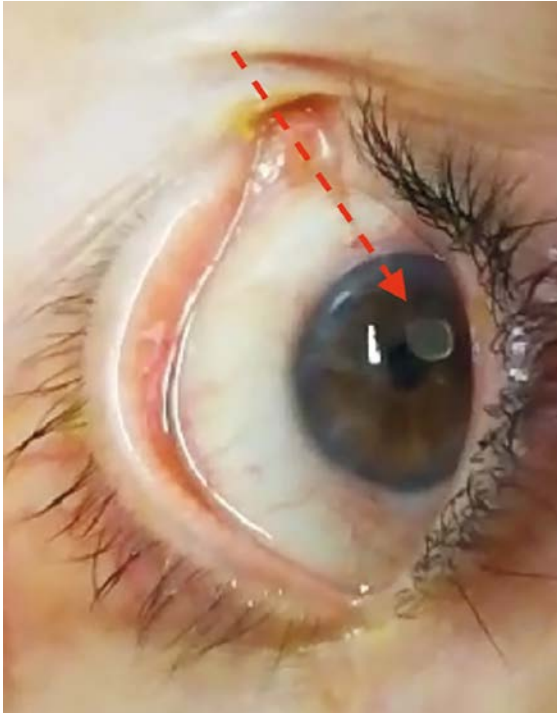
Published online: 8 November 2023

---

Acta Medica (Hradec Králové) 2023; 66(2): 72–74

<https://doi.org/10.14712/18059694.2023.19>

© 2023 The Authors. This is an open-access article distributed under the terms of the Creative Commons Attribution License (<http://creativecommons.org/licenses/by/4.0>), which permits unrestricted use, distribution, and reproduction in any medium, provided the original author and source are credited.



**Fig. 1** Grade 1 conjunctival redness and cystic lesion.

## INTRODUCTION

There is limited literature regarding free-floating anterior chamber cysts and cystic-like lesions with most of them being pigmented iris cysts (1–6). In this case report we describe a sodium hyaluronate free-floating cyst-like lesion in the anterior chamber following uncomplicated phacoemulsification.

## CASE REPORT

An 83-year-old man underwent uncomplicated phacoemulsification for stage 2 LOCS-III cataract, and received a foldable monofocal intraocular lens (IOL) in his left eye. Following surgery, he was prescribed fixed combination of tobramycin & dexamethasone (FCTD) q.i.d. and 0.1% sodium hyaluronate q.i.d. For non-medical reasons, the patient missed his first postoperative follow-up examination (1 week postop) and scheduled for the 2nd postoperative visit at 4 weeks. However, 20 days postoperatively,

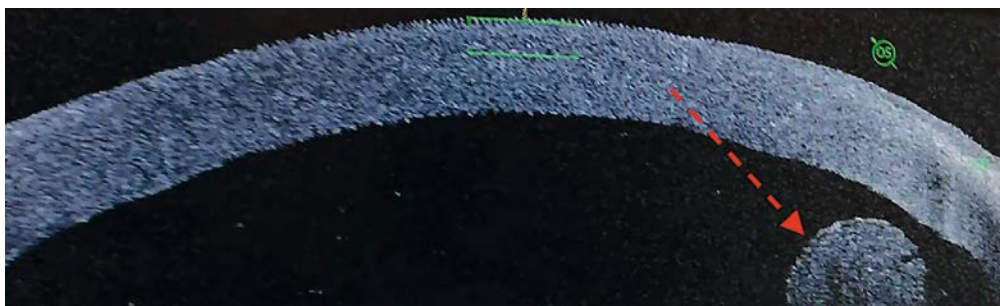
he urgently visited our outpatient service due to transient blurring of vision, and ocular redness. He reported that blurred vision was aggravated during certain activities, such as leaning down or lying in bed. On the other hand, he reported no visual disturbances when standing.

Uncorrected Distance Visual Acuity (UDVA) was logMAR 0.1 and intraocular pressure was 18 mmHg. Slit-lamp biomicroscopy revealed a round, clear, non-pigmented, free-floating cystic-like structure in the anterior chamber. With the patient standing, the cystic structure was almost hidden at the top (12th hour) of the anterior chamber; on the other hand, during certain head postures, it occasionally obstructed the visual axis. No inflammatory cells could be detected in the anterior chamber. Despite that fact, grade 1 conjunctival redness could be detected. Anterior segment optical coherence tomography (AS-OCT) visualized the free-floating structure; however, it presented as a uniform, solid structure and not a cyst (Figures 1, 2).

Immediate surgical extraction was decided, and the cystic-like lesion was successfully removed. When extracted from the anterior chamber it was dissolved in a clear gelatinous substance (Figures 3, 4). Histopathological examination returned no organic cells, but sodium hyaluronate. Three months following extraction surgery, UDVA remains at logMAR 0.1 with symptom-free quality of vision.

## DISCUSSION

A variety of cystic-like lesions have been reported in the anterior chamber. Differential diagnosis includes an iris cyst, a non-keratinized squamous epithelium cyst and cysticercosis. In our case, lack of the pigmentation of the inner wall (1) made the diagnosis of an iris cyst less probable (6), as well as its appearance on OCT imaging, presenting as an equally hyperreflective lesion, internally and externally, with typical OCT findings of hyperreflective walls and hypo-reflective internal structure being the most common (7–8). On the other hand, cysticercosis cysts show characteristic contracting and expanding movements with the presence of a live scolex as a dense white spot (9). Histopathological examination confirmed sodium-hyaluronate, which, to our knowledge, is the first incident to be reported and should be taken into consideration as a rare complication in an otherwise uncomplicated phacoemulsification.



**Fig. 2** AS-OCT appearance of the lesion.

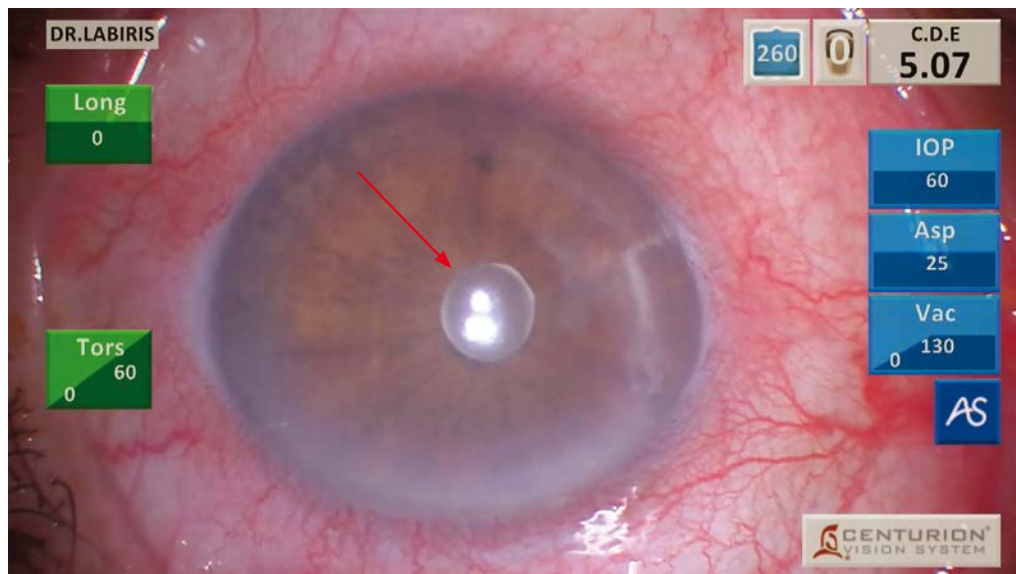


Fig. 3 Photograph of the lesion on surgery day.

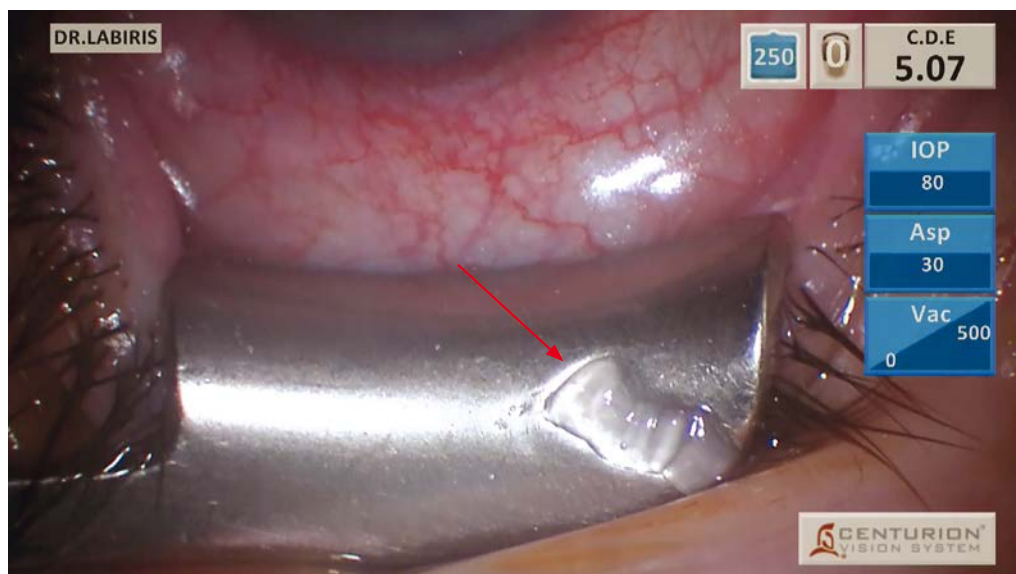


Fig. 4 Cystic lesion dissolved in a clear gelatinous substance.

## CONCLUSIONS

Such lesions have not been reported in the literature. The appearance of cysts after cataract surgery is relatively rare and usually consist of epithelial cells. In our case, the prognosis was good and the patient made a full recovery.

## FINANCIAL DISCLOSURE

No financial support was received for this case report. None of the authors has any proprietary interests or conflicts of interest related to this submission. It is not simultaneously being considered for publication at any other journal.

## REFERENCES

1. Singh G, Narendran K, Saravanan VR, Narendran V. Pigmented free-floating iris cysts. *Br J Ophthalmol* 2007; 91(8): 1037.
2. Paysse EA, Coats DK. Free-floating cyst in the anterior chamber. *Arch Ophthalmol* 1998; 116: 1256-7.
3. Shields JA, Shields CL, DePotter P, Wagner RS, Caputo AR. Free-floating cyst in the anterior chamber of the eye. *J Pediatr Ophthalmol Strabismus* 1996; 33: 330-1.
4. Lu CW, Liu XF, Qu LM. Pigmented Free-Floating Iris Cyst in the Anterior Chamber. *Ophthalmology* 2022; 129(10): 1151.
5. Arora M, Satpute K, Verma S, Singh A. Free-floating iris cyst in the anterior chamber *BMJ Case Reports CP* 2022; 15: e253527.
6. Malta JB, Banitt M, Soong HK. Free floating cyst in anterior chamber after cataract surgery. *Br J Ophthalmol* 2008; 92(7): 911.
7. Köse HC, Gündüz K, Hoşal MB. Iris Cysts: Clinical Features, Imaging Findings, and Treatment Results. *Turk J Ophthalmol* 2020; 50(1): 31-6.
8. Georgalas I, Petrou P, Papaconstantinou D, Brouzas D, Koutsandrea C, Kanakis M. Iris cysts: A comprehensive review on diagnosis and treatment. *Surv Ophthalmol* 2018; 63(3): 347-64.
9. Takkar B, Mehdi MU, Ahmed NR, Chandra P, Vanathi M. Anterior segment optical coherence tomography of live ocular cysticercosis. *Clin Experiment Ophthalmol* 2014; 42: 896-8.