



# Successful Pregnancy Outcome after Amnioreduction Treated Acute Polyhydramnios Caused by Duodenal Atresia

Edin Medjedovic<sup>1, 2</sup>, Zlatan Zvizdic<sup>3</sup>, Anis Cerovac<sup>4, 5, \*</sup>, Sabaheta Jonuzovic-Prosic<sup>1</sup>, Emir Milisic<sup>3</sup>

## ABSTRACT

The aim of our manuscript is to report of a successful perinatal outcome after treatment of acute polyhydramnios caused by duodenal atresia.

A 34-year-old G3P1 was referred due to polyhydramnios in the 30th week of pregnancy. Ultrasound revealed polyhydramnios, amniotic fluid index (AFI) 28, and a double bubble sign that indicated duodenal atresia and dilated oesophagus. In the 32nd week of gestation, the volume of amniotic fluid increases, AFI 35, along with symptoms of dyspnea and abdominal pain. Due to the clinical picture and the early gestational age, it was decided to perform an amnioreduction. In the 36th week of gestation cesarean section was performed. The baby was taken for exploratory laparotomy and found to have a simultaneous complete duodenal atresia and annular pancreas with associated dilated the first portion of the duodenum and the stomach. A side-to-side duodenoduodenostomy via single-layer hand-sewn anastomosis was performed over a transanastomotic feeding tube (TAFT). The postoperative course was uneventful. Amnioreduction is useful and safe in the treatment of acute polyhydramnios caused by duodenal atresia and thus has a significant role in prolonging gestation until fetal maturity.

## KEYWORDS

polyhydramnios; pediatric surgery; invasive ultrasound; antenatal care

## AUTHOR AFFILIATIONS

<sup>1</sup> Clinic of Gynecology and Obstetrics, Clinical Center University of Sarajevo, Sarajevo, Bosnia and Herzegovina

<sup>2</sup> Department of Gynecology, Obstetrics and Reproductive Medicine, School of Medicine, Sarajevo School of Science and Technology, Sarajevo, Bosnia and Herzegovina

<sup>3</sup> Clinic of Pediatric Surgery, University Clinical Center Sarajevo, Sarajevo, Bosnia and Herzegovina

<sup>4</sup> General Hospital Tešanj, Department of Gynaecology and Obstetrics, Bosnia and Herzegovina

<sup>5</sup> University of Tuzla, School of Medicine, Bosnia and Herzegovina

\* Corresponding address: General Hospital Tešanj, Braće Pobrić 17, 74260 Tešanj, Bosnia and Herzegovina; e-mail: cerovac.anis@gmail.com

Received: 1 October 2022

Accepted: 21 January 2023

Published online: 16 March 2023

Acta Medica (Hradec Králové) 2022; 65(4): 149–152

<https://doi.org/10.14712/18059694.2023.6>

© 2022 The Authors. This is an open-access article distributed under the terms of the Creative Commons Attribution License (<http://creativecommons.org/licenses/by/4.0>), which permits unrestricted use, distribution, and reproduction in any medium, provided the original author and source are credited.

## INTRODUCTION

Congenital duodenal obstruction (CDO) is a frequent cause of intestinal obstruction, representing up to 60 percent of all cases of neonatal intestinal obstructions, and occurs in approximately one infant per 10,000 births (1). Early prenatal diagnosis of CDO is not possible, due to underdeveloped gastric emptying, which prevents dilatation of the duodenum. Duodenal atresia is rarely recognized until 20 to 24 weeks of pregnancy when the characteristic “double bubble” ultrasound sign and polyhydramnios become apparent (2, 3).

The average time of prenatal diagnosis of CDO has been reported late in pregnancy at around 30 weeks of gestation (ranging from 20 to 38 weeks of gestation). Polyhydramnios can be a sign of high bowel atresia due to the lack of re-absorption of amniotic fluid, and presence of polyhydramnios varies from 30% to 80% (2, 3). Prenatal detection of CDO with polyhydramnios and “double bubble” sign is present in 45% of cases on antenatal ultrasound examination (2, 3). Chromosomal defects, mainly trisomy 21, are found in 30% of cases of CDO (2, 3).

Polyhydramnios represents an excessive accumulation of amniotic fluid, when the amniotic fluid index is greater than 25 or the volume of one pocket of amniotic fluid is greater than 8, and its prevalence ranges from 1–2% (4).

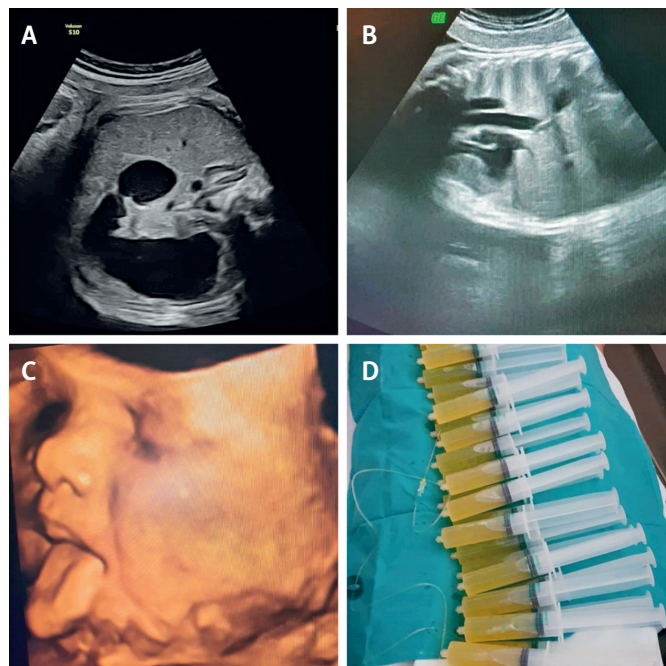
Sometimes polyhydramnios can be associated with a negative perinatal outcome; fetal anomalies and chromosomopathies, fetal anemia, maternal diabetes and infections, premature birth, but it can also be idiopathic (4).

Amnioreduction is a widely accepted treatment for polyhydramnios in twin to twin transfusion syndrome before laser ablation of vascular anastomoses, but its use in the treatment of acute polyhydramnios in singleton pregnancies has rarely been published (4, 5). To the best of our knowledge, in our country so far one case report has been published regarding a successfully performed amnioreduction before the placement of an emergency cerclage, after which the pregnancy was extended for 17 weeks and ended with a successful neonatal outcome (6).

The aim of our manuscript is to report of a successful perinatal outcome after treatment of acute polyhydramnios caused by duodenal atresia.

## CASE REPORT

A 34-year-old G3P1 was referred to the Clinic due to polyhydramnios in the 30th week of pregnancy. Ultrasound revealed polyhydramnios, amniotic fluid index (AFI) 28, and a double bubble sign that indicated duodenal atresia and dilated oesophagus (Figure 1A and 1B). The patient was hospitalized and monitored. In the 32nd week of gestation, the volume of amniotic fluid increases, AFI 35, along with symptoms of dyspnea and abdominal pain. On figure 1C we show how the foetus regurgitates amniotic fluid from mouth (Figure 1C). Due to the clinical picture and the early gestational age, it was decided to perform an amnioreduction. With this procedure, 1700 ml of amniotic fluid is evacuated and sent for cytogenetic analysis, after which an orderly cytogenetic finding was obtained (Figure 1D),



**Fig. 1** A: Double bubble sign at ultrasound that indicated duodenal atresia; B: Oesophageal dilatation; C: The fetus regurgitates water, D: Amnioreduction of 1700 ml of amniotic fluid.

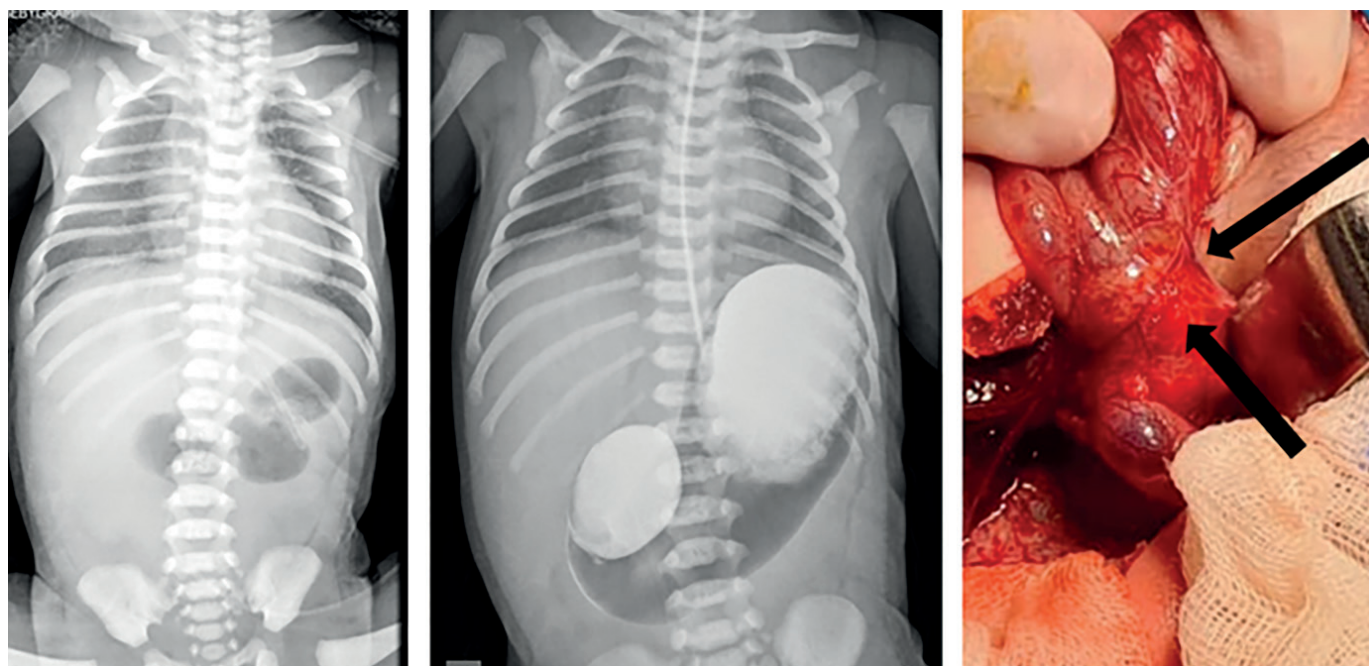
after which the AFI was reduced to 22. Fifteen days later, polyhydramnios develops again, the amnioreduction was repeated, and 1600 ml of amniotic fluid was evacuated. In the 36th week of gestation, AFI was 30, and the fetus was in breech presentation. Course of antenatal corticosteroids as respiratory distress syndrome prophylaxis was administered. Cesarean section was performed 48 hours later and delivered female newborn with birth weight and length 3350/52, and Apgar score in first and fifth minute 7 and 10. Postpartum diagnostic work-up confirmed the antenatal diagnosis by abdominal radiograph with barium contrast depicts the double-bubble sign of duodenal atresia (Figure 1A).

After correcting dehydration and electrolyte imbalance the baby was taken on day two for exploratory laparotomy through a right subcostal approach and found to have a simultaneous complete duodenal atresia and annular pancreas (Figure 2B) with associated dilated the first portion of the duodenum and the stomach. A side-to-side duodenoduodenostomy via single-layer hand-sewn anastomosis was performed over a transanastamotic feeding tube (TAFT). A nasogastric tube was placed in the stomach for proximal decompression.

The postoperative course was uneventful, enteral nutrition through TATF was introduced on the second postoperative day and achieved on full feeds on a postoperative day 5. The baby was discharged in stable condition and kept in regular follow-up.

## DISCUSSION

In our case, duodenal atresia in the presence of polyhydramnios was detected in the 30th week of pregnancy, when it is most often detected (2, 3).



**Fig. 2** A: The abdominal radiograph with barium contrast depicts the double-bubble sign of duodenal atresia; B: Intraoperative finding of duodenal atresia (the atretic part of the duodenum is under the surgeon's fingers, and the annular pancreas is at the level of the right Farabef hook).

Amnioreduction was performed on two occasions, in which the amniotic fluid was reduced by 1700 ml and 1600 ml, which correlates with literature recommendations that no more than 2000 ml to 2500 ml should be removed (4). Amnioreduction in our case prolonged the duration of pregnancy by 4 weeks, it was also performed without potential complications such as placental abruption and premature prelabour rupture of fetal membranes (4, 5).

Dickinson et al. in their retrospective study of all singleton pregnancies receiving amnioreduction for polyhydramnios concluded that amnioreduction has a useful role in the management of polyhydramnios, that complications are uncommon and delivery typically occurs near term (4).

Dickinson et al. found that median gestation when the first amnioreduction was performed was 31 weeks, median amniotic fluid volume removed was 2100 ml, median duration from amnioreduction to delivery was 26 days, median gestation at delivery was 36.4 weeks. In 4.1% of procedures, an unplanned preterm birth occurred within 48 hours of the procedure (4). The final diagnosis in neonates from this study was gastrointestinal malformations (21%), idiopathic (20.3%), chromosomal (15.2%), syndromic (13.7%) and neurologic (8%) (4).

The prognosis for duodenal obstruction is highly dependent on the presence or absence of associated anomalies. In isolated duodenal obstruction, the survival rate is >95%; there is a wide variation in mortality rate in complicated cases, dependent on the nature of the associated anomalies (2, 3). Duodenal obstruction is associated with a high rate of prematurity, possibly because of polyhydramnios, and an increased rate of unexpected fetal demise (2, 3).

Congenital duodenal obstruction (CDO) may be either partial or complete, extrinsic or intrinsic, or even both.

Important intrinsic causes of CDO include duodenal atresia, stenosis, and webs, while extrinsic CDO may be caused by the annular pancreas, malrotation, or preduodenal portal vein (2). An association between duodenal atresia (DA) and the annular pancreas has only occasionally been found simultaneously (7-11), including in our present case.

## CONCLUSION

Amnioreduction is useful and safe in the treatment of acute polyhydramnios caused by duodenal atresia and thus has a significant role in prolonging gestation until fetal maturity. Prenatal ultrasound recognition of duodenal atresia allows the multidisciplinary approach of obstetricians, neonatologists, pediatric surgeons, and anesthesiologists to surgically correct it in time and enable an optimal neonatal outcome.

## CONFLICT OF INTEREST

The authors have nothing to disclose and no conflict of interest to declare. No funding source was involved in this study and there are no financial or other relationships that could be perceived to influence the manuscript.

## ETHICAL APPROVAL

This is a case report, for which there is no requirement of our institution to seek permission of the Ethics Committee to publish a paper. We obtained a required patient's family permission.

## REFERENCES

1. Bethell GS, Long AM, Knight M, Hall NJ; BAPS-CASS. Congenital duodenal obstruction in the UK: a population-based study. *Arch Dis Child Fetal Neonatal Ed* 2020; 105(2): 178–83.
2. Saalabian K, Friedmacher F, Theilen TM, Keese D, Rolle U, Gfroerer S. Prenatal Detection of Congenital Duodenal Obstruction-Impact on Postnatal Care. *Children (Basel)* 2022; 9(2): 160.
3. Bishop JC, McCormick B, Johnson CT, et al. The Double Bubble Sign: Duodenal Atresia and Associated Genetic Etiologies. *Fetal Diagn Ther* 2020; 47(2): 98–103.
4. Dickinson JE, Tjioe YY, Jude E, Kirk D, Franke M, Nathan E. Amnioreduction in The Management of Polyhydramnios Complicating Singleton Pregnancies. *Am J Obstet Gynecol* 2014; 211(4): 434.e1–7.
5. Thompson A, Mone F, McComiskey M, Ong S. Amnioreduction in a singleton pregnancy: A systematic review. *J Obstet and Gynaecol* 2013; 33:764–7.
6. Medjedovic E, Begic Z, Suljevic A, Muftic A, Dzihic E, Kurjak A. Amnioreduction in Emergency Rescue Cervical Cerclage with Bulging Membranes. *Med Arch* 2020; 74(2): 151–2.
7. Rattan KN, Singh J, Dalal P. Neonatal duodenal obstruction: a 15-year experience. *J Neonatal Surg* 2016; 5(2): 13.
8. Baumgartner F, Moore TC. Atretic, obstructive proximal duodenal mass associated with annular pancreas and malrotation in a newborn male. *Eur J Pediatr Surg* 1992; 2(1): 42–4.
9. Glüer S, Petersen C, Ure BM. Simultaneous correction of duodenal atresia due to annular pancreas and malrotation by laparoscopy. *Eur J Pediatr Surg* 2002; 12(6): 423–5.
10. Papandreou E, Baltogiannis N, Cigliano B, Savanelli A, Settimi A, Karamidas D. Annular pancreas combined with distal stenosis. A report of four cases and review of the literature. *Pediatr Med Chir* 2004; 26: 256–9.
11. Yoon Y, Dragusin IB, Gallagher ME, Clark P. VACTERL syndrome with late presentation of annular pancreas with duodenal web: Case report. *Radiol Case Rep* 2022; 17(6): 1853–7.