

THE MANAGEMENT OF CHARCOT MIDFOOT DEFORMITIES IN DIABETIC PATIENTS

Pavel Šponer^{1,2}, Tomáš Kučera^{1,2}, Jindra Brtková³, Jaromír Šrot²

Charles University in Prague, Faculty of Medicine in Hradec Králové, Czech Republic: Department of Orthopaedic Surgery¹, University Hospital in Hradec Králové, Czech Republic: Department of Orthopaedic Surgery², Department of Diagnostic Radiology³

Summary: Charcot foot neuropathic osteoarthropathy is a disorder affecting the soft tissues, joints, and bones of the foot and ankle. The disease is triggered in a susceptible individual through a process of uncontrolled inflammation leading to osteolysis, progressive fractures and articular malpositioning due to joint subluxations and dislocations. The progression of the chronic deformity with a collapsed plantar arch leads to plantar ulcerations because of increased pressure on the plantar osseous prominences and decreased plantar sensation. Subsequent deep soft tissue infection and osteomyelitis may result in amputation. The Charcot foot in diabetes represents an important diagnostic and therapeutic challenge in clinical practice. Conservative treatment remains the standard of the care for most patients with neuropathic disorder. Offloading the foot and immobilization based on individual merit are essential and are the most important recommendations in the active acute stage of the Charcot foot. Surgical realignment with stabilization is recommended in severe progressive neuropathic deformities consisting of a collapsed plantar arch with a rocker-bottom foot deformity.

Key words: *Diabetes mellitus; Foot; Charcot neuropathic osteoarthropathy*

Introduction

Neuropathic arthropathy is relatively rare but important and devastating disorder described as the progressive destruction of bone and joints in a patient with peripheral neuropathy. Jean Martin Charcot noted the relationship between syphilis and severe arthropathy in 1868 (19). Diabetes mellitus is currently the most common cause of Charcot arthropathy of the foot, affecting between 0.1 and 2.5% of patients with diabetes mellitus (28). The Charcot foot syndrome is a serious and potentially limb-threatening lower extremity complication in diabetic patients. The disease is triggered in a susceptible individual through a process of uncontrolled inflammation leading to osteolysis, progressive fractures and dislocations (29). The classic rocker-bottom foot represents a severe chronic deformity that is typical for this condition. The progression of the longitudinal foot arch collapse may lead to plantar osseous prominences with soft-tissue compromise and subsequent ulceration, infection, and osteomyelitis resulting in amputation. Thus, in diabetes, the Charcot foot represents an important diagnostic and therapeutic challenge in clinical practice.

Definition

Charcot foot neuropathic osteoarthropathy is a disorder affecting the soft tissues, joints, and bones of the foot and ankle. The condition begins as an acute uncontrolled

localized inflammation that may lead to osseous destruction associated with articular malpositioning due to subluxation and dislocation. After this active acute stage, the midfoot deformity may evolve to include possible midfoot instability and, ultimately, open plantar ulceration (15).

Pathogenesis

The Charcot foot arthropathy affects diabetic patients with severe peripheral neuropathy in both lower extremities and autonomic neuropathy (32). The loss of protective sensation increases the likelihood of microtrauma to the foot, while autonomic neuropathy results in increased blood flow to the limb and contributes to soft tissue swelling and local osteoporosis (15).

As the peripheral neuropathy progresses in long-standing diabetes and the proprioception is altered, a process of uncontrolled inflammation in the foot may be triggered by minor trauma, local inflammation, or recent foot surgery. During uncontrolled inflammation, increased peripheral blood flow and active bone resorption lead to bone and joint destruction. The loss of pain sensation allows for uninterrupted walking with repetitive trauma. This activity results in the continual production of proinflammatory cytokines, receptor activator of nuclear factor kappa-B ligand (RANKL), nuclear factor kappa-light-chain-enhancer of activated B cells (NF-κB), and osteoclasts, which in turn leads to continual local osteolysis with progressive bone and joint destruction (16, 29).

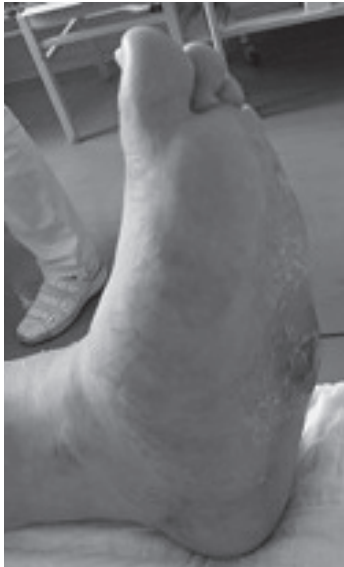

Fig. 1: Typical clinical appearance of the chronic-stage Charcot neuropathic osteoarthropathy with the rocker-bottom foot deformity

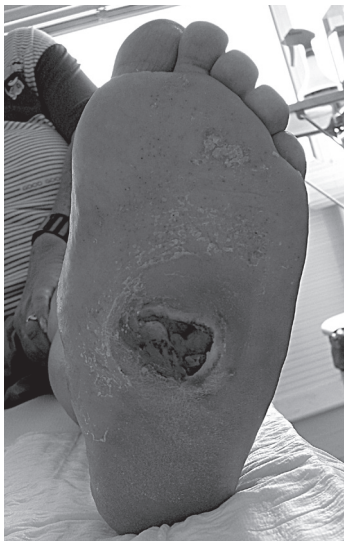

Fig. 2: Plantar ulcer grade 2 according to the Wagner classification in the same patient

Diagnosis

The diagnosis of active acute Charcot foot is primarily based on the history and clinical findings (4). The disease is triggered in a susceptible individual by minor trauma, local inflammatory processes, including previous ulceration and infection, or recent foot surgery and successful revascularization (29). The initial clinical manifestations of the disorder are often mild and develop with repetitive trauma due to reduced pain sensation. The typical clinical outcome includes a markedly swollen, warm, and frequently erythematous foot, which is usually associated with only mild to moderate pain or discomfort. The temperature difference between the affected and the contralateral foot can reach several degrees (3). Although a neurally mediated vascular reflex leads to increased peripheral blood flow, pedal pulses are actually obscured by foot oedema. The initial acute local inflammatory changes are often the earliest sign of underlying bone and joint destruction in neuropathic patients (17).

During the chronic stage of Charcot neuropathic osteoarthropathy, the skeletal deformities may progress to a severe rocker-bottom foot deformity with a collapsed plantar arch (Fig. 1, 2). The midfoot instability is evaluated according to Assal by applying stress to the forefoot in the sagittal plane with the ankle joint locked in dorsiflexion. An abnormal midfoot motion is assessed through the use of this clinical test (5). Increased pressure on the osseous plantar prominences and the decreased plantar sensation cause plantar ulcerations, which are classified using the Wagner classification system (33). This classification grades diabetic foot ulcers based on the depth of tissue penetration and necrosis (Table 1). Low grades are generally infected with gram-positive microorganisms, and higher grades tend to be caused by polymicrobial flora with an increased number of aerobic gram-negative bacteria and anaerobes (1). The cultures should be obtained from open plantar ulcerations and also from the deep tissue layers, particularly from bones, to identify particular microbial flora and adapt the antibiotic therapy on the basis of the culture results. Osteomyelitis frequently accompanies deep neuropathic ulcers and presents a difficult diagnostic challenge because both deep soft-tissue infection and bone infection have the same clinical picture, which consists of fever, uncontrolled serum glucose level, purulent drainage, and lymphangitis (15). Limb-threatening ischemia can develop in diabetic patients with chronic deformities. Doppler ultrasonography and digital subtraction angiography may be used to evaluate peripheral vessel involvement.

Because patients with diabetic neuropathy have insensate feet and do not complain of pain, a yearly screening with the 5.07/10-g Semmes-Weinstein monofilament has been recommended for the rapid identification of the disorder (13). Transcutaneous oximetry is helpful for the evaluation of wound healing potential because diabetic patients have a high rate of associated vascular disease. A pressure ≥ 30 mm Hg

Tab. 1: Wagner classification of diabetic foot ulcerations

Grade	Definition
Zero	No ulcer
One	Superficial skin ulcer
Two	Deep ulcer extending through dermis. Tendon, ligaments, joint capsule or bone may be exposed
Three	Deep ulcer with abscess, osteomyelitis, or joint sepsis
Four	Localized gangrene of the forefoot or heel
Five	Gangrene of the foot

was noted in the study with successful use of the axial intramedullary fixation of the medial foot column (5).

Plain radiographs are the initial imaging method for the evaluation of bone structure, foot alignment and skeletal mineralization in diabetic patients. Dorsoplantar and lateral weight-bearing radiographs should be taken. The radiographic changes of the Charcot foot are delayed, and these radiographs may have low sensitivity (24). In the acute stage, the radiographs may be normal. Gradually, subtle subluxations and subchondral fractures can be displayed (15). These symptoms can be visualized better and earlier by CT. In later stages, the dorsoplantar and lateral talus-first metatarsal angle, the lateral calcaneus-fifth metatarsal angle and the calcaneal inclination angle should be measured for the proper assessment of forefoot, midfoot and hindfoot

alignment with progressive skeletal deformities (Fig. 3). The 3D CT reconstructions may be helpful in planning the surgical realignment and stabilization in severe neuropathic deformities (Fig. 4).

Magnetic resonance imaging allows for the early detection of subtle changes in the acute stage of the Charcot neuropathic osteoarthropathy before such changes become evident on plain radiographs (Fig. 5). Magnetic resonance imaging is often unable to differentiate acute osteoarthropathy from osteomyelitis (1, 5). In addition, a cost-analysis of diabetic foot infection treatment revealed that non-invasive testing for osteomyelitis adds significant expense to the treatment costs with little impact on the outcomes (1).

Three-phase bone scintigraphy with ^{99m}Tc is highly sensitive for active bone pathologic processes, but it is not

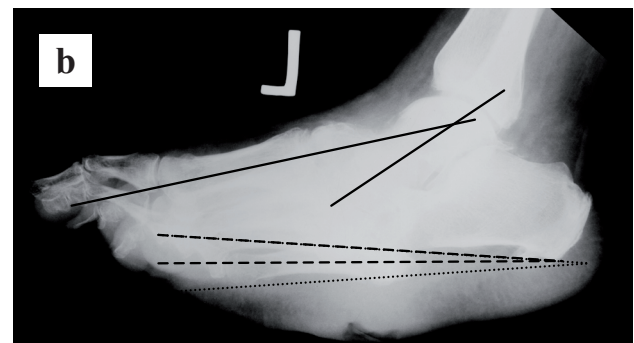
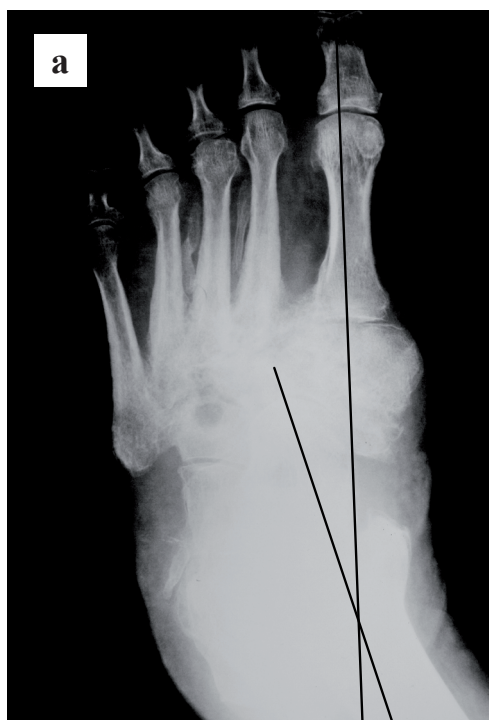
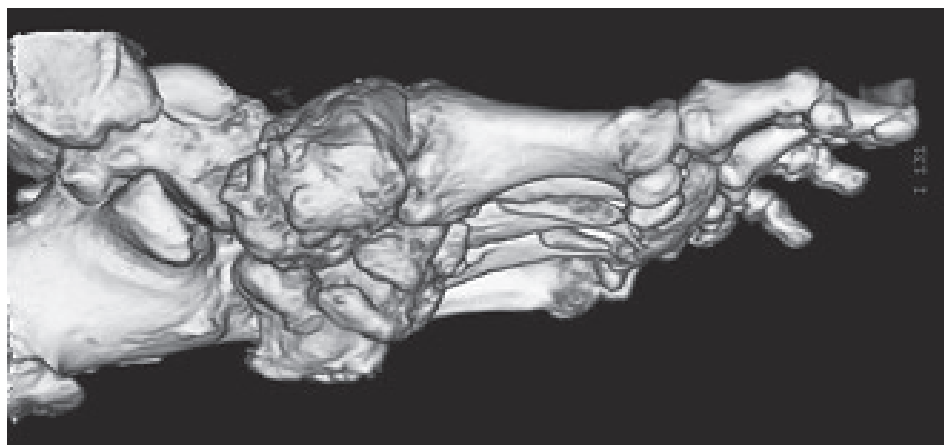


Fig. 3: Preoperative plain radiographs, a) dorsoplantar view with apparent dorsoplantar talus-first metatarsal angle (solid lines), b) lateral view with marked lateral talus-first metatarsal angle (solid lines), calcaneal inclination angle (dashed lines), and lateral calcaneus-fifth metatarsal angle (dotted lines)

Fig. 4: Preoperative 3D CT imaging of the left foot, the osseous destruction and plantar prominences visible on medial view



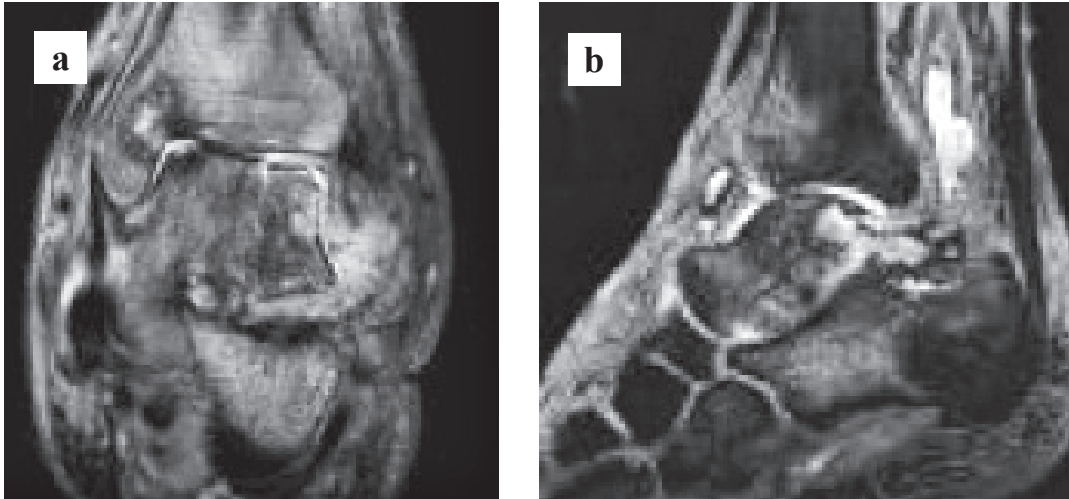


Fig. 5: Inflammatory involvement of the hindfoot with subchondral fractures of the dorsolateral part of the talus, a) coronal view, b) sagittal view

specific for osteoarthropathy, and diminished circulation can result in false negative results. Labelled white blood cell scanning with ^{99m}Tc or ^{111}In provides improved specificity for infection, but it cannot differentiate between soft tissue infection and osteomyelitis. The evaluation of bone density in diabetic patients using dual-energy X-ray absorptiometry may be useful to assess the fracture risk.

Treatment

Treatment guidelines are widely based on professional opinion because of the limited surveys in this area, and the optimal treatment protocol remains an issue of debate (5). Conservative treatment remains the standard of care for most patients with neuropathic disorders.

Offloading the foot and immobilization based on individual merit are essential and are the most important recommendations in the active acute stage of the Charcot foot (32). An irremovable total contact cast is initially frequently replaced to avoid pistoning as the oedema subsides in the first few weeks of treatment. The use of crutches or a wheelchair is required to avoid weight bearing on the affected side. The casting should continue until the swelling has resolved and the temperature of the affected side is within 2°C of that of the contralateral foot (3). It should be emphasized that total immobility leads to the loss of muscle tone, reduction of bone density and loss of body fitness. The alternative device for offloading in the active acute stage of the Charcot foot is the Charcot restraint orthotic walker (23). This device is a customized bivalved total contact ankle-foot orthosis made from a positive plaster mould of the involved lower extremity and consists of a rigid polymer shell lined with specific foams of different densities. The duration and character of offloading are based on the clinical subsidence of oedema, erythema, skin temperature

changes and the evidence of healing on radiographs or MRI. The prescriptive shoes, boots, or weight-bearing braces with frequent monitoring are recommended after an active acute stage to prevent the recurrence of ulceration or the occurrence subsequent deformities (29). In diabetic patients with active Charcot neuropathic osteoarthropathy, treatment with antiresorptive pharmacotherapy has been proposed, but there is little evidence to support the use of bisphosphonates and calcitonin in the healing process (2, 6, 27).

The open plantar ulcers should be nonoperatively treated with wound care consisting of local debridement, antibiotic therapy, and total contact casting (8). It is clinically unfeasible to differentiate between the deep soft tissue infection and bone infection in the Charcot foot using MRI or other diagnostic tests. Therefore, it is recommended to treat all deep soft tissue infections as osteomyelitis with urgent intervention (5). Debridement and irrigation of the wound with cultures are performed after the diabetic patient is admitted to the hospital, and wide spectrum antibiotics are administered until the culture results are available. Based on these results, the antibiotic therapy is adjusted, and the wounds should be checked daily. The antibiotic therapy is continued until the active infection is resolved, as indicated by the return of the laboratory tests to normal and the cessation of drainage.

A combination of vacuum assisted closure therapy and mesh grafting is useful after initial necrectomy in diabetic patients with peripheral neuropathy (7). The efficiency of muscle flaps in the therapy of complex foot and ankle deformities seems to be possible in some patients with diabetes mellitus, nevertheless further studies are necessary (14).

Surgical treatment is beneficial in progressive deformities that are refractory to conservative treatment with the development of recalcitrant plantar ulcerations as a result

of increased plantar pressure on the insensate feet. Lengthening of the Achilles or gastrocnemius tendon combined with total contact casting can reduce the forefoot pressure and realign the ankle and hindfoot to the midfoot and forefoot (25). Resection of osseous plantar prominences in patients with a stable Charcot foot deformity may reduce the pressure caused by bone prominences. Simple exostectomy can be followed with accommodative bracing (10, 20). This less technically demanding and less morbid procedure has generally poor results in unstable Charcot foot deformities because the collapse progresses with the recurrence of plantar osseous prominences and ulceration (12).

Surgical realignment with stabilization is recommended to restore the plantigrade foot in severe neuropathic deformities consisting of a collapsed plantar arch with a

rocker-bottom foot deformity and associated nonhealing plantar ulceration (5). Another indication for surgical reconstruction is a progressive rocker-bottom deformity with midfoot instability without plantar ulceration (30). Recently, early correction of the deformity combined with arthrodesis has been reported (22). The reconstruction of the Charcot foot deformity is technically difficult, has potential complications, and requires patient compliance over a prolonged period of treatment. The correction and stabilization of the Charcot foot deformity with a neutrally applied three level ring external fixator has been reported as an effective method in relatively immune-impaired diabetic patients with a poor bone quality and a tenuous soft tissue envelope (16, 26, 35). The type of internal fixation used is extremely important in the reconstruction of Charcot foot deformities because of the poor bone healing and inherent weakness of the underlying bone structures in the insensate feet. The reduction of the deformity and arthrodesis using standard methods of single joint fixation with smaller screws to restore a plantigrade foot are associated with the risk of loss of initial correction, failure, and

Fig. 6: Clinical appearance of the foot after surgical realignment and internal stabilization

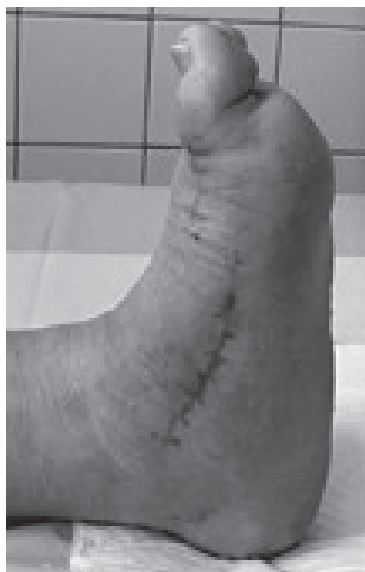

Fig. 7: Completely healed plantar ulceration

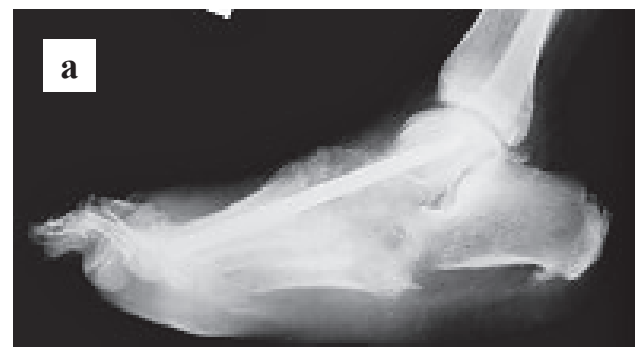
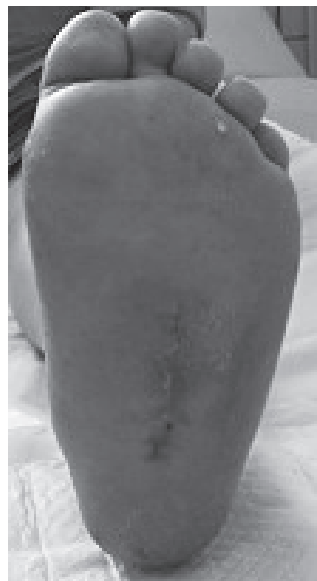
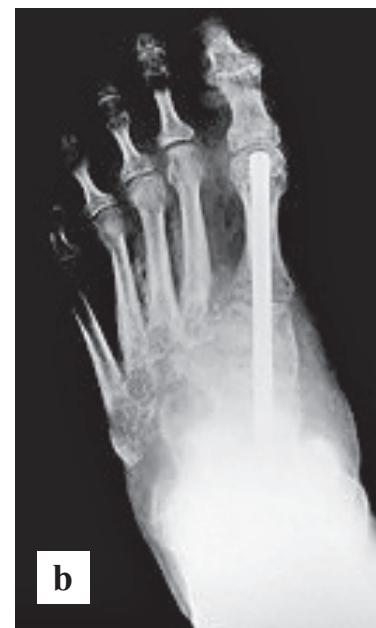Fig. 8: Postoperative plain radiographs, a) axial intramedullary fixation of the medial column extending beyond the zone of fusion from talus to first metatarsal, b) healing of the talonavicular, navicular-cuneiform and 1st metatarsal-cuneiform joint fusions on dorsoplantar view



nonunion despite an extended period of non-weightbearing after surgery (9, 21). The dissection of soft tissues is necessary for the medial plate fixation and may increase the risk of wound complications and reduce the blood supply to the bone. The technique of axial intramedullary fixation of the medial column was introduced to reduce these risks (30). In this concept of an internal fixation superconstruct, long intramedullary screws extend beyond the zone of fusion from the talus to the first metatarsal in the medial column and from the calcaneus to the fifth metatarsal in the lateral column (Figs 6–8). The main advantage of the axial intramedullary fixation is the restricted dissection needed to insert the screw compared to placing the medial plate fixation (5). The reported union rate of an extended fusion with a strict non-weightbearing regimen for the first four postoperative months ranged from 73 to 83% (5, 31). The reconstruction of the Charcot foot deformity can prevent the need for amputations that provide an immediate solution but increase the energy required for walking in diabetic patients with frequently associated cardiac and vascular compromise (11, 34). The development of the Charcot deformity on the contralateral foot may lead to increased pressure with subsequent plantar ulceration, infection and osteomyelitis, possibly resulting in amputation. In patients with diabetes, 28 to 51% undergo a second amputation within five years after an initial amputation (28).

Acknowledgements

This work was supported by the programme PRVOUK P 37/04 and by MHCZ – DRO (UHHK, 00179906).

References

- Adams CA, Deitch EA. Diabetic foot infections. In: Holzheimer RG, Mannick JA, eds. Surgical treatment: evidence-based and problem-oriented. Munich: Zuckschwerdt, 2001.
- Anderson JJ, Woelffer KE, Holtzman JJ et al. Bisphosphonates for the treatment of Charcot neuroarthropathy. *J Foot Ankle Surg* 2004; 43: 285–9.
- Armstrong DG, Lavery LA. Monitoring healing of acute Charcot's arthropathy with infrared dermal thermometry. *J Rehabil Res Dev* 1997; 34: 317–21.
- Armstrong DG, Todd WF, Lavery LA et al. The natural history of acute Charcot's arthropathy in a diabetic foot specialty clinic. *Diabet Med* 1997; 14: 357–63.
- Assal M, Stern R. Realignment and extended fusion with use of a medial column screw for midfoot deformities secondary to diabetic neuropathy. *J Bone Joint Surg Am* 2009; 91: 812–20.
- Bem R, Jirkovská A, Fejřarová V et al. Intranasal calcitonin in the treatment of acute Charcot neuroosteoarthropathy: a randomized controlled trial. *Diabetes Care* 2006; 29: 1392–4.
- Beno M, Martin J, Sager P. Vacuum assisted closure in vascular surgery. *Bratislav Lek Listy* 2011; 112: 249–52.
- Boninger ML, Leopard JA. Use of bivalved Antle foot orthosis in neuropathic foot and ankle lesion. *J Rehabil Res Dev* 1996; 33: 16–22.
- Bono JV, Roger DJ, Jacobs RL. Surgical arthrodesis of the neuropathic foot: A salvage procedure. *Clin Orthop Rel Res* 1993; 296: 14–20.
- Brodsky JW, Rouse AM. Exostectomy for symptomatic bony prominence in diabetic Charcot feet. *Clin Orthop Rel Res* 1993; 296: 21–6.
- Buse JB, Ginsberg HN, Bakris GL et al. American Heart Association; American Diabetes Association. Primary prevention of cardiovascular diseases in people with diabetes mellitus: a scientific statement from the American Heart Association and American Diabetes Association. *Diabetes Care* 2007; 30: 162–72.
- Catanzariti AR, Mendicino R, Haverstock B. Osteotomy for diabetic neuroarthropathy of the midfoot. *Am J Orthop* 2007; 39: 291–300.
- Cornblath DR. Diabetic Neuropathy: Diagnostic methods. *Adv Stud Med* 2004; 4: S650–61.
- Ducic I, Attinger CE. Foot and ankle reconstruction: pedicled muscle flaps versus free flaps and the role of diabetes. *Plast Reconstr Surg* 2011; 128: 173–80.
- Dungl P. *Ortopedie*. 1st ed. Praha: Grada Publishing, 2005: 1161–4.
- Farber DC, Juliano PJ, Cavanaugh PR et al. Single stage correction with external fixation of the ulcerated foot in individuals with Charcot neuroarthropathy. *Foot Ankle Int* 2002; 23: 130–4.
- Jeffcoate W. The cause of the Charcot syndrome. *Clin Podiatr Med Surg* 2008; 25: 29–42.
- Jeffcoate WJ, Game F, Cavanagh PR. The role of proinflammatory cytokines in the cause of neuropathic osteoarthropathy (acute Charcot foot) in diabetes. *Lancet* 2005; 366: 2058–61.
- Kučera T, Urban K, Šponer P. Charcot arthropathy of the knee. A case-based review. *Clin Rheumatol* 2011; 30: 425–8.
- Laurinaviciene R, Kirketerp-Moeller K, Hostein PE. Exostectomy for chronic midfoot plantar ulcer in Charcot deformity. *J Wound Care* 2008; 17: 53–5.
- Marks RM, Parks BG, Schon LC. Midfoot fusion technique for neuropathic feet: biomechanical analysis and rationale. *Foot Ankle Int* 1998; 19: 507–10.
- Mittlmeier T, Klauke K, Haar P et al. Should one consider primary surgical reconstruction in Charcot arthropathy of the foot? *Clin Orthop Rel Res* 2010; 468: 1002–11.
- Morgan JM, Biehl WC, Wanger FW. Management of neuropathic arthropathy with the Charcot restraint orthotic walker. *Clin Orthop Rel Res* 1993; 296: 58–63.
- Morrison WB, Ledermann HP. Work-up of the diabetic foot. *Radiol Clin North Am* 2002; 40: 1171–92.
- Mueller MJ, Sinacore DR, Hastings MK et al. Impact of Achilles tendon lengthening on functional limitations and perceived disability in people with a neuropathic plantar ulcer. *Diabetes Care* 2004; 27: 1559–64.
- Pinzur MS. Neutral ring fixation for high-risk nonplantigrade Charcot midfoot deformity. *Foot Ankle Int* 2007; 28: 961–6.
- Pitocco D, Ruotolo V, Valuto S et al. Six-month treatment with alendronate in acute Charcot neuroarthropathy: a randomized controlled trial. *Diabetes Care* 2005; 28: 1214–1215.
- Reiber GE, Lipsky BA, Gibbons GW. The burden of diabetic foot ulcers. *Am J Surg* 1998; 176: 5S–10S.
- Rogers LC, Frykberg RG, Armstrong DG et al. The Charcot foot in diabetes. *J Am Pod Med Ass* 2011; 101: 437–46.
- Rooney J, Hutabarat S, Grujic L, Hansen S. Surgical reconstruction of the neuropathic foot. *The foot* 2002; 12: 213–23.
- Sammarco VJ, Sammarco GJ, Walker EW, Guiao RP. Midtarsal arthrodesis in the treatment of Charcot midfoot arthropathy. *J Bone Joint Surg Am* 2009; 91: 80–91.
- Singh R, Bhalla A, Sachdev A, Lehl SS. Diabetic Neuropathic Arthropathy. *Int J Diab Dev Countries* 2000; 20: 135–8.
- Wagner F. A classification and treatment program for diabetic, neuropathic, and dysvascular foot problems. *Instr Course Lect* 1979; 28: 143–65.
- Waters R, Perry J, Chambers R. Energy expenditure of amputee gait. In: Moore W, Malone JM, eds. Lower extremity amputation. Philadelphia: W B Saunders, 1989: 250–60.
- Wukich DK, Belczyk RJ, Burns PR. Complications encountered with circular ring fixation in persons with diabetes mellitus. *Foot Ankle Int* 2008; 29: 994–1000.

Received: 02/10/2012

Accepted in revised form: 03/01/2013

Corresponding author:

Assoc. Prof. MUDr. Pavel Šponer, Ph.D., University Hospital, Sokolská 581, 500 05 Hradec Králové, Czech Republic;
e-mail: pavel.sponer@fnhk.cz