

Endoscopic Injection Treatment of Vesicoureteral Reflux in Children: Meeting with the Factors Involved in the Success Rate

Stylianos Roupakias^{1,*}, Xenophon Sinopidis¹, Ioannis Spyridakis², George Tsikopoulos³, Ageliki Karatza⁴, Anastasia Varvarigou⁴

ABSTRACT

The challenges and controversies in vesicoureteral reflux intervention guidelines resulted in a more individualized treatment planning. Endoscopic injection therapy is now widely used and is considered preferable, but still remains less successful than ureteral reimplantation. The endoscopic vesicoureteral reflux approach should be risk-adapted to current knowledge, so more experience and longer-term follow-up are needed. The precise of preoperative, intraoperative, and postoperative factors that affecting endoscopic injection therapy success rates and outcome have not yet been clearly determined.

The aim of this study was to investigate these associated factors. Although the reflux grade is the most well-known factor that can affect the success of the procedure, there is no agreement on which factors are the most influential for the efficacy of endoscopic reflux treatment. So, we carried out a broad review of published papers on this topic, and we presented all the potential predictive variables of endoscopic reflux resolution in children.

KEYWORDS

vesicoureteral reflux; children; endoscopic; injection; outcome; risk factors

AUTHOR AFFILIATIONS

¹ Department of Pediatric Surgery, University of Patras Medical School, Patra, Greece

² Department of Pediatric Surgery, Aristotelian University of Thessaloniki Medical School, Thessaloniki, Greece

³ Department of Pediatric Surgery, Hippocrateion General Hospital, Thessaloniki, Greece

⁴ Department of Pediatrics, University of Patras Medical School, Patra, Greece

* Corresponding author: Pediatric Surgeon, University of Patras Medical School, 74 Hatzigiorgi str. Volos 38333, Greece; e-mail: stylroup@yahoo.gr

Received: 18 June 2021

Accepted: 16 October 2021

Published online: 4 March 2022

Acta Medica (Hradec Králové) 2021; 64(4): 193–199

<https://doi.org/10.14712/18059694.2022.1>

© 2021 The Authors. This is an open-access article distributed under the terms of the Creative Commons Attribution License (<http://creativecommons.org/licenses/by/4.0>), which permits unrestricted use, distribution, and reproduction in any medium, provided the original author and source are credited.

INTRODUCTION

Vesicoureteral reflux (VUR), as the most common and controversial urological abnormality in children, with a prevalence of 1% to 2%, is the most frequent predisposing risk factor for acute pyelonephritis, nephropathy with renal scarring, and decreased renal function (1). Renal damage may be congenital or acquired after infection, and the aim of the VUR-facilitating factor management is to prevent recurrent or breakthrough urinary tract infections, new renal scarring formation, and relative renal function deterioration (2). We can no longer view VUR as a homogeneous entity affecting all individuals equally. In contrary, we should take into consideration individual parameters and specific factors for a case by case and risk to benefit based deciding VUR management (1, 3).

Endoscopic injection treatment (EIT) became initially a popular alternative to open surgical ureteral reimplantation and long-term antibiotic prophylaxis in pediatric VUR management, as a minimally invasive and well tolerated method with a relatively short learning curve and low complication rate (4). Endoscopic treatment of a bulking agent was pioneered by Matouschek in 1981 (5) and was further developed and popularized by O'Donnell and Puri, who reported their experimental and clinical endoscopic Teflon injection results in 1984 (6). Since then, a lot of different substances have been used until the introduction of Deflux (7). EIT is nowadays recommended in selected centers as the first line therapy when intervention is needed (8, 9). It is considered preferable to ureteral reimplantation, which may be reserved for exclusive use in children not responding to EIT (9). In addition, parents of children with VUR are very likely to express a preference for EIT among all alternative options proposed (10). While open ureteral reimplantation has a maximum reported success rate of 98%, the most recently reported maximum radiographic EIT short-term cure rate is about 94% (11). Although EIT provides approximately a medium 80% cure rate, concerns about its long-term efficacy and delayed complications have resulted in a controversy over its real usefulness in recent years (4). Delayed post-injection ureteral obstruction is rare but may occur years post-operatively (11). EIT needs further evaluation of long-term outcomes (1).

Researchers have reported a variable success rate 50–94% of EIT, indicating differences in study design and methodology (12). There is significant disagreement on what a successful EIT constitutes, between the absence and the downgrading (presence of grade I-II or ≥ 2 grades improvement) of VUR, in combination or not with a recurrent febrile urinary tract infection (UTI) after injection (11, 12). One more or multiple reinjection procedures are frequently necessary in about 10–30% of cases with failed EIT (13, 14). Persistent VUR, is defined as that which is present three months after EIT, detected by follow-up cystography (15). In addition, reflux can recur in about 5–25% of children after a successful EIT (16, 17). Recurrent VUR, is defined as a proven VUR by repeated voiding cystourethrography (VCUG) in children with febrile UTI, any time after the first negative post-EIT cystography follow-up (15).

EIT success is evaluated in a short period of time, as in most studies it is determined after three months from the injection. If follow-up periods were longer, the recurrence rate might be higher (18, 19). There are reports of recurrence VUR rates as high as 26% after one year and 54% after two years from EIT (18). Fresh development of contralateral reflux after EIT for unilateral VUR is reported in the literature as well (9, 20). Persistent or recurrent VUR puts the children at risk for further UTIs and possible kidney damage. The precise pre/peri/post-operative factors affecting EIT success rates and outcome have not yet been clearly determined (21, 22). There is no agreement on which factors are the most influential for the endoscopic resolution of VUR, even with the use of artificial neural networks (23). We report the studies with positive correlation of factors with EIT cure rate, although there are many with opposite results.

EIT TECHNIQUE

EIT involves submucosal injection of a bulking agent to provide tissue augmentation and to improve the ureteral orifice valve mechanism (9, 24) (Figure 1). In the traditional STING (Subureteral Transurethral Injection) procedure, the needle is introduced under the bladder mucosa 2–3 mm below the refluxing orifice (9, 24). In the intraluminal HIT (hydrodistension implantation technique) technique, which has increased the success rate significantly (from 80% to 90%) (9, 16, 25–27), the needle is introduced into the mucosa inside the ureteral tunnel (9, 24). The advantages of HIT over STING include better visualization of the distal ureteral lumen with the aid of hydrodistension, more accurate placement of the injector needle at the desired position, better coaptation of ureteral orifice (27). In addition, the HIT technique has statistically significant success rate against STING technique for high grade reflux cases (28). Unlikely, other multivariate analyses have failed to demonstrate a significant difference in outcomes between the two techniques (22, 29, 30). The double HIT technique, currently achieving the highest success rates, involves one proximal and a second distal intraluminal ureteral injection site (9, 15). A combination of HIT and STING techniques can be performed in cases of HIT failure to coapt the ureter (31).

BULKING AGENTS

Over the years, many injectable agents have been investigated but only few of them are widely used. Thousands of children have been treated with different agents. Only four – Teflon, Deflux, Collagen, Silicone/Macroplastique – have been used in humans in large enough numbers to enable assessment of effectiveness (16, 32). The risk of new renal scarring is greatest among infants and young children aged under 5 years and therefore, the bolus created, using an injectable substance should persist for at least a period of 3 to 5 years (9). Deflux is now the most widely used and the most extensively studied bulking agent, which completely substituted the Teflon (16). Silicone/

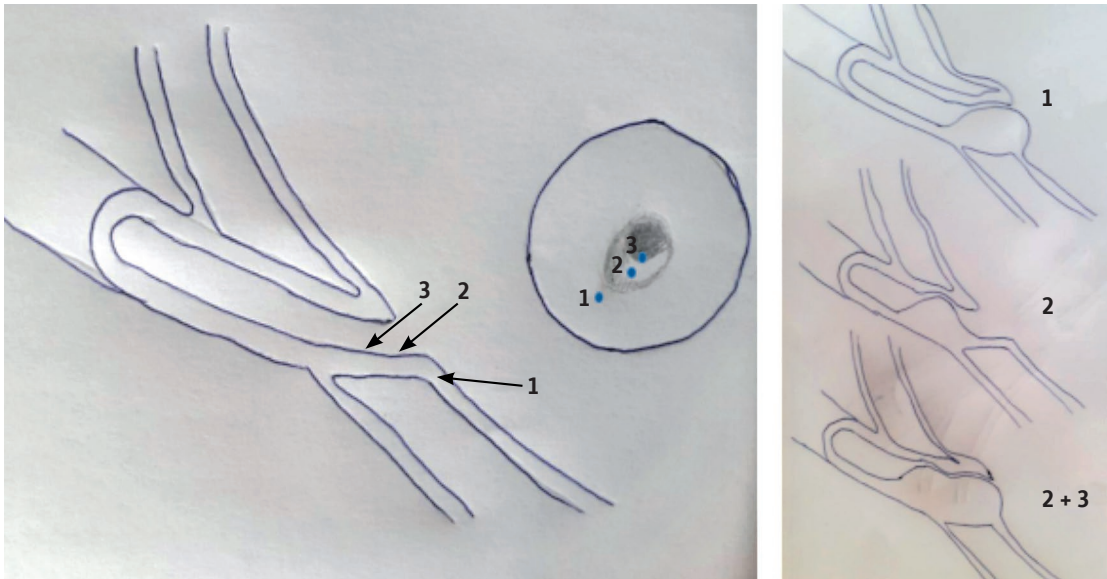


Fig. 1 Algorithm of endoscopic technique injection sites (1 = STING, 2 = HIT, 2 + 3 = Double HIT).

Macroplastique has been used with effectiveness that approaches that of Deflux (16). Biocompatibility of the substance, lack of potential for migration from the injection site, and absence of fibrosis or aggressive granulomatous reaction spreading to adjacent tissue are the ideal properties for the dominant or preferable injectable agent (4, 9, 12). The use of new polymer agents, like polydimethylsiloxane and polytetrafluoroethylene, is related with less recurrence rate in comparison with Deflux (33).

Studies have reported an increased success rate with the injected Vantris polymer agent and approved it as a more effective and promising material (with better stability and long-term durability) regardless of other confounding variables and the EIT technique (4, 34–39). In addition, Vantris presents more efficacy against Deflux in high grade VUR cure (40). However, ureteral obstruction and severe fibrosis on injection site are more commonly seen with Vantris use, and long-term data should be followed (4, 39–42). In a recent study, Vantris is presented as a completely effective agent for treating all high grade (IV–V) of primary (100% success rate after the second injection) and complex (100% success rate after the third injection) VUR in children, with the significant disadvantage of late (occurred within 3 years of EIT) severe ureteral obstruction in 8% of patients, that required surgical reimplantation (43).

PERIOPERATIVE FACTORS

There is a significant correlation between the endoscopically showed shapes of the ureteral orifice and their hydro-distension grade before the injection with the VUR grades and the EIT outcome (26, 44, 45). The cure rate in children with golf-hole type orifices is significantly lower than that of other types (46). The creation of a mound that elevates and coapts the orifice is the most important factor determining the success of EIT (4, 29). This volcano

mound after the injection morphology of ureteral orifice is associated with a statistically significant increase in reflux resolution (19, 22, 45). The achievement of a mound mass height measuring 9.8 mm in maximal vertical diameter, at intraoperative ultrasound simultaneously with endoscopic procedure, maintains a significant correlation with EIT success (47). On the other hand, moderate injected volume >1 ml is a significant predictor of treatment failure (22). Intraoperative cystography following injection may help to determine immediate success and identify cases of new contralateral reflux but there is insufficient correlation with the standard 3-month postoperative VCUG (48). Thus, intraoperative cystography fails to show clinical utility to predict the EIT outcome (49).

LEARNING CURVE OF EIT

Independently of the technique used, there has been a learning curve associated with endoscopic VUR correction (50). EIT cure rates related to the surgeon are increasing and the requirement for reinjections decreasing as experience with the technique is improved (21, 46, 51). A combination of adequate experience and great skill in EIT is required to obtain results that could be favorably comparable to ureteral reimplantation, because there is a strong belief that nearly all endoscopic failures are related to unrecognized or unappreciated technical errors (9). In one study, success rates increased from 60% for the first 20 of 134 patients, to 80% for the last 20 cases (52). With increasing experience, not only high grade primary VUR, but also secondary reflux (duplex system), are considered eligible for EIT (51, 53). A multivariate analysis demonstrates that physician experience is an independent predictor of endoscopic VUR correction rates (54). Physician's experience and adjustments in clinical-surgical practice are associated with a reduced ureteral reimplantation rate (51, 55).

VUR GRADE AND MULTIPLE INJECTIONS

VUR grades II–III are considered as middle grade reflux and grades IV–V as high. In systematic reviews the reported success rates were 80–90% for grade I, 79–84% for grade II, 72% for grade III, 59–63% for grade IV, and 51–62% for grade V (56, 57). Lower success rates are presented in higher grades of VUR (19, 21, 46, 57, 58), and application of second and third injections increases the success rates (21, 46, 57). EIT is successful in about 50% of children with high grade VUR, and multiple injection procedures are frequently necessary to achieve a success rate about 85% (16). In a study, reflux was cured after the first STING injection in 100% of the ureters with grade II reflux, 65% of the ureters with grade III reflux and 50% of the ureters with grade IV reflux (28). The overall success rate increased with the second STING injection to 73% and 67% for grades III and IV reflux (28). Reflux was cured after the first HIT injection in 100% of the ureters with grade II reflux, 74% of the ureters with grade III reflux and 55% of the ureters with grade IV reflux (28). The overall success rate increased with the second HIT injection to 85% and 76% for grades III and IV reflux (28). Repeated EIT procedures are found to be successful in grade III and IV VUR, but children presenting with grade V should undergo ureteral reimplantation if the first trial of EIT results in failure as repeated injections have been proved unsuccessful in this grade (59). Recently, increasing evidence has been emerging to support the use of EIT in children with grade V VUR (24, 43, 60).

OTHER PREOPERATIVE FACTORS

Age is found to be a significant predictive factor of EIT success (40). Puri et al. presented their experience with endoscopic treatment of VUR in infants less than 12 months of age, asked about the necessity to overcome general anesthesia in such young patients with increased rate of VUR resolution over time (61). We can perform EIT in infants (62, 63), but we should rather not, because the effectiveness is lower than in children treated at an older age, there is not much experience, and the incidence of high-grade VUR is significantly higher as DMSA changes too (62). Age ≥ 6 years is a positive predictor (22), and age < 1 year is a negative predictor of EIT success (33, 64). Younger age, especially age of 0–12-month-old, is a significant predictor of postoperative febrile UTI recurrence (65).

Radiologic success of EIT is statistically less common in males compared to females (66). There is a significant positive correlation between grade, bilaterality, recurrent preinjection UTIs, history of voiding dysfunction, defects on DMSA scan, and persistent or recurrent VUR after EIT (67). A study revealed that younger age, grade IV–V VUR and renal scarring are significant variables for the failure of endoscopic treatment after the first injection (68).

VCUG timing for VUR is found to be an independent factor for VUR resolution after EIT, and a filling reflux has significant lower success rate than a voiding reflux, especially in children with high grade VUR (69). Ureters that refluxed during the voiding phase have an approximately

threefold independent odds of successful EIT, compared to those that refluxed during bladder filling (70). Distal ureteral diameter ratio at preoperative VCUG provides an objective measurement of VUR and appears as a predictive tool for clinical outcome and success after EIT (71, 72). It is significantly higher in children with high grade VUR and/or DMSA renal uptake $\leq 40\%$ (72). Its predictive value for EIT success is more significant than VUR grade (72).

Renal scars on preoperative scintigraphy are significantly associated with postoperative febrile UTI and possible EIT failure (15, 21). Renal units with preoperative DMSA changes (hypoplasia, scars, uptake $\leq 40\%$) are at higher recurrence and lower cure risk, as a possible result of maldevelopment (15, 19, 46, 72, 73).

A factor that influences VUR resolution is voiding dysfunction, which refers to the presence of bladder filling and/or emptying lower urinary tract symptoms (urge, incontinence, weak stream, hesitancy, frequency, accompanying bowel problems) (1). Bilaterality is also a significant prognostic factor for the success rate of EIT (65–71). The success rate of EIT is significantly reduced in the presence of abnormal voiding habits, and additional injections are needed (21, 33, 74, 75). Duplicated systems and complex cases of VUR have lower cure rates (4, 31, 45), but are not associated with EIT failure (29, 31, 55). More recent studies have reported better success rates after a single injection (43, 55, 60, 76, 77).

It seems clear that a girl with high grade VUR and DMSA changes is at relatively high risk for recurrence than a boy with low grade VUR and no DMSA changes (15). Children aged less than two years or with ≥ 3 preoperative febrile UTI or with documented voiding dysfunction or with grade IV–V VUR, are 13 times more likely to have EIT failure (78). Children with ≥ 2 predictive factors, including febrile UTI, voiding dysfunction, and/or defects on DMSA, may not be optimal candidates for EIT (67).

POSTOPERATIVE FACTORS

Postoperative febrile UTI is significantly associated with EIT failure (21). Recurrences of febrile UTI may occur after 3 years of follow up and within the first 5 years after EIT (79, 80). Children with > 3 episodes of recurrent preinjection UTI are 8.5 times more likely than those with only one episode to have an infection after EIT (67, 81). Female sex, older children and voiding dysfunction are the most important risk factors in the development of febrile UTI during long-term follow-up after successful EIT correction of VUR (81, 82). Furthermore, reinjections in children with postoperative febrile UTI and grade III–IV VUR seem to be unsuccessful (21). Mound detection at the first postoperative ultrasound is most critical factor than the intraoperative mound shape, and a strong and more reliable predictor of a successful EIT outcome (19, 45, 66). Calculated ellipsoid volume (CEV) of injected agent mounds is defined as $4/3\pi \times \text{height}/2 \times \text{length}/2 \times \text{width}/2$, based on 3-months postoperative ultrasound dimensions (22, 45). $\text{CEV} > 25\%$ of injected agent volume is a positive predictor of EIT success (22, 31). The achievement of a maximal mound height in transverse vesical section measuring

at least 10 mm at three months postoperative ultrasound suggests a major predictive parameter for VUR resolution after EIT (64).

CONCLUSIONS

With the wide use of EIT and long-term follow-up, more treatment failures are being encountered, despite the accumulated endoscopic experience and the apparent by time success rates improvement. There is no agreement on which factors are the most influential for EIT successfulness. The risk factors affecting the outcome of EIT management for VUR studied herein are summarized in Table 1. The high grade VUR and treatment at infancy, as well as the presence of positive DMSA or urinary dysfunction, are factors associated with reflux persistence or recurrence after EIT. The preoperative filling than voiding VUR and the large ureteral diameter at VCUG are strong independent predictive factors for EIT failure. Duplex ureters are no longer considered as a contraindication for EIT. Even with widespread experience, the success rate in high grade VUR with a single injection of any of the available agents still fails to equal that of following ureteral reimplantation. Vantris is a new promising bulking agent for additional improvement of the double HIT method's

Tab. 1 Risk factors affecting the outcome of VUR endoscopic injection therapy.

VUR grade
Re-injections
Endoscopic technique
Bulking agent
Surgical endoscopic experience
Age (≥ 6 or ≤ 1 years old)
Gender
DMSA scan defects (hypoplasia, renal scar, uptake $\leq 40\%$)
Recurrent preinjection UTIs
Post-injection UTIs
Voiding dysfunction history
Bilateral VUR
Double ureteral system
VCUG timing of VUR (filling vs voiding)
Preoperative-VCUG distal ureteral diameter ratio
Endoscopically showed shapes of the ureteral orifice
Hydro-distension grade of the ureteral orifice
Endoscopically creation of a volcano mound
Moderate injected volume >1 ml
Intraoperative ultrasound mound mass height
Postoperative ultrasound mound volume (3 months)
Postoperative ultrasound mound mass height (3 months)

Abbreviations: vesicoureteral reflux (VUR), urinary tract infection (UTI), hydrodistension implantation technique (HIT), voiding cystourethrography (VCUG).

results. Postoperative febrile UTI and/or poor ultrasound visualization of the ureteral orifice mound suggest negative predictive parameters for VUR cure after EIT. The endoscopic VUR approach should be risk-adapted to current knowledge. More experience and longer-term follow-up are needed. More prompt and aggressive approach with ureteral reimplantation is mandatory for children who have grade V VUR and low success rate at the beginning.

REFERENCES

1. Roupakias S, Sinopidis X, Karatza A, Varvarigou A. Predictive risk factors in childhood urinary tract infection, vesicoureteral reflux, and renal scarring management. *Clin Pediatr* 2014; 53: 1119-33.
2. Roupakias S, Sinopidis X, Tsikopoulos G, Spyridakis I, Karatza A, Varvarigou A. Dimercaptosuccinic acid scan challenges in childhood urinary tract infection, vesicoureteral reflux and renal scarring investigation and management. *Minerva Urol Nefrol* 2017; 69: 144-52.
3. Hajiyev P, Burgu B. Contemporary Management of Vesicoureteral Reflux. *Eur Urol Foc* 2017; 3: 181-8.
4. Kim SW, Lee YS, Han SW. Endoscopic injection therapy. *Investig Clin Urol* 2017; 58: 38-45.
5. Matouschek E. Treatment of vesicorenal reflux by transurethral teflon-injection. *Der Urologe Ausg A* 1981; 20: 263-4.
6. O'Donnell b, Puri P. Treatment of vesicoureteric reflux by endoscopic injection of Teflon. *Br Med J (Clin Res Ed)* 1984; 289: 7-9.
7. Stenberg A, Lackgrten G. A new bioimplant for the endoscopic treatment of vesicoureteral reflux: Experimental and short-term clinical result. *J Urol* 1995; 154: 800-3.
8. Fuentes S, Gómez-Fraile A, Carrillo-Arroyo I, Tordable-Ojeda C, Cabezalí-Barbancho D. Endoscopic Treatment of Vesicoureteral Reflux in Infants. Can We Do It and Should We Do It? *Urology* 2017; 110: 196-200.
9. Läckgren G, Kirsch AJ. Surgery Illustrated - Surgical Atlas Endoscopic treatment of vesicoureteral reflux. *BJU Int* 2010; 105: 1332-47.
10. Capozza N, Lais A, Matarazzo E, Nappo S, Patricolo M, Caione P. Treatment of vesico-ureteric reflux: A new algorithm based parental preference. *BJU Int* 2003; 92: 285-8.
11. Lightfoot M, Bilgutay AN, Tollin N, et al. Long-Term clinical outcomes and parental satisfaction after Dextranomer/Hyaluronic acid (Dx/HA) injection for primary vesicoureteral reflux. *Front Pediatr* 2019; 7: 392.
12. Kim JW, Oh MM. Endoscopic treatment of vesicoureteral reflux in pediatric patients. *Korean J Pediatr* 2013; 56: 145-50.
13. Garcia-Aparicio L, Rovira J, Blazquez-Gomez E, et al. Randomized clinical trial comparing endoscopic treatment with dextranomer hyaluronic acid copolymer and Cohen's ureteral reimplantation for vesicoureteral reflux: long-term results. *J Pediatr Urol* 2013; 9: 483-7.
14. Chertin B, Natsheh A, Fridmans A, Shenfeld OZ, Farkas A. Renal scarring and urinary tract infection after successful endoscopic correction of vesicoureteral reflux. *J Urol* 2009; 182: 1703-7.
15. Haid B, Berger C, Roesch J, et al. Persistence and recurrence of vesicoureteric reflux in children after endoscopic therapy - implications of a risk-adapted follow-up. *Cent European J Urol* 2015; 68: 389-95.
16. Okawada M, Esposito C, Escolino M, et al. Treatment of vesico-ureteral reflux in infants and children using endoscopic approaches. *Transl Pediatr* 2016; 5: 282-90.
17. Friedlander DA, Ludwig WW, Jayman JR, Akhavan A. The effect of prior endoscopic correction of vesicoureteral reflux on open ureteral reimplantation: Surgical outcomes and costs. *J Pediatr Urol* 2018; 14: 268.e1-5.
18. Lee EK, Gatti JM, Demaro RT, Murphy JP. Long-term follow-up of dextranomer/hyaluronic acid injection for vesicoureteral reflux: late failure warrants continued follow up. *J Urol* 2009; 181: 1869-74.
19. Jung HJ, Im YJ, Lee YS, Kim MJ, Han SW. Is a secondary procedure necessary in every case of failed endoscopic treatment for vesicoureteral reflux? *Korean J Urol* 2015; 56: 398-404.
20. Chertin B, Natsheh A, Fadeev D, Shenfeld OZ, Farkas A. Unilateral vesicoureteral reflux warranting routine bilateral endoscopic correction. *J Urol* 2008; 180: 1601-3.
21. Akin Y, Gulmez H, Güntekin E, Baykara M, Yucel S. Retrospective study of endoscopic treatment in children with primary vesicoureteral reflux and multivariate analysis of factors for failure. *Scand J Urol* 2014; 48: 565-70.

22. Watters ST, Sung J, Skoog SJ. Endoscopic treatment for vesicoureteral reflux: how important is technique? *J Pediatr Urol* 2013; 9: 1192–7.
23. Serrano-Durbá A, Serrano AJ, Magdalena JR, et al. The use of neural networks for predicting the result of endoscopic treatment for vesico-ureteric reflux. *BJU Int* 2004; 94: 120–2.
24. Läckgren G. Endoscopic treatment of vesicoureteral reflux: Current status. *Indian J Urol* 2009; 25: 34–39.
25. Routh JC, Reinberg Y, Ashley RA, et al. Multivariate comparison of the efficacy of intraureteral versus subtrigonal techniques of dextranomer/hyaluronic acid injection. *J Urol* 2007; 178: 1702–5.
26. Kirsch AJ, Perez-Brayfield M, Smith EA, Scherz HC. The modified sting procedure to correct vesicoureteral reflux: Improved results with submucosal implantation within the intramural ureter. *J Urol* 2004; 171: 2413–6.
27. Yap TL, Chen Y, Nah SA, Ong CC, Jacobsen A, Low Y. STING versus HIT technique of endoscopic treatment for vesicoureteral reflux: A systematic review and meta-analysis. *J Pediatr Surg* 2016; 51: 2015–20.
28. Karabacak OR, Yalçinkaya F, Altuğ U, Sertçelik N, Demirel F. Does the Modified STING Method Increase the Success Rate in the Management of Moderate or High-Grade Reflux? *Korean J Urol* 2014; 55: 615–9.
29. Yucel S, Gupta A, Snodgrass W. Multivariate analysis of factors predicting success with dextranomer/hyaluronic acid injection for vesicoureteral reflux. *J Urol* 2007; 177: 1505–9.
30. Gupta A, Snodgrass W. Intra-orifice versus hydrodistension implantation technique in dextranomer/hyaluronic acid injection for vesicoureteral reflux. *J Urol* 2008; 180: 1589–92.
31. Cerwinka WH, Scherz HC, Kirsch AJ. Endoscopic treatment of vesicoureteral reflux with dextranomer/hyaluronic acid in children. *Adv Urol* 2008; 513854: 1–7.
32. Chertin B, Puri P. Endoscopic management of vesicoureteral reflux: does it stand the test of time? *Eur Urol* 2002; 42: 598–606.
33. Fuentes S, Gómez-Fraile A, Carrillo-Arroyo I, et al. Factors involved in the late failure of endoscopic treatment of vesicoureteral reflux. *Actas Urol Esp* 2018; 42: 331–7.
34. Starmer B, McAndrew F, Corbett H. A review of novel STING bulking agents. *J Pediatr Urol* 2019; 15: 484–90.
35. Ormaechea M, Ruiz E, Denes E, et al. New tissue bulking agent (polyacrylate polyalcohol) for treating vesicoureteral reflux: Preliminary results in children. *J Urol* 2010; 183: 714–7.
36. Alizadeh F, Omid I, Haghdani S, Hatef Khorrami M, Izadpanahi MH, Mohammadi Sichani M. A comparison between dextranomer/hyaluronic acid and polyacrylate polyalcohol copolymer as bulking agents for treating primary vesicoureteral reflux. *Urol J* 2019; 16: 174–9.
37. Warchol S, Krzemien G, Szmigielska A, Bombinski P, Brzewski M, Dudek-Warchol T. Comparison of results of endoscopic correction of vesicoureteral reflux in children using two bulking substances: Dextranomer/hyaluronic acid copolymer (Deflux) versus polyacrylate-polyalcohol copolymer (Vantris). *J Pediatr Urol* 2016; 12: 256.e1–4.
38. Taşkınlar H, Avlan D, Bahadır GB, Delibaş A, Nayci A. The outcomes of two different bulking agents (dextranomer hyaluronic acid copolymer and polyacrylate-polyalcohol copolymer) in the treatment of primary vesico-ureteral reflux. *Int Braz J Urol* 2016; 42: 514–20.
39. Karakus SC, User IR, Kılıç BD, Akçaer V, Ceylan H, Ozokutan BH. The comparison of dextranomer/hyaluronic acid and polyacrylate-polyalcohol copolymers in endoscopic treatment of vesicoureteral reflux. *J Pediatr Surg* 2016; 51: 1496–1500.
40. Kocaoglu C. Endoscopic treatment of grades IV and V vesicoureteral reflux with two bulking substances: Dextranomer hyaluronic acid copolymer versus polyacrylate polyalcohol copolymer in children. *J Pediatr Surg* 2016; 51: 1711–5.
41. Şencan A, Yıldırım H, Özkan KU, Uçan B, Karkınar A, Hoşgör M. Late ureteral obstruction after endoscopic treatment of vesicoureteral reflux with polyacrylate polyalcohol copolymer. *Urology* 2014; 84: 1188–93.
42. Kajbafzadeh AM, Sabetkish S, Khorramirouz R, Sabetkish N. Comparison of histopathological characteristics of polyacrylate polyalcohol copolymer with dextranomer/hyaluronic acid after injection beneath the bladder mucosa layer: a rabbit model. *Int Urol Nephrol* 2017; 49: 747–52.
43. Warchol S, Krzemien G, Szmigielska A, Bombinski P, Toth K, Dudek-Warchol T. Endoscopic correction of vesicoureteral reflux in children using polyacrylate-polyalcohol copolymer (Vantris): 5-years of prospective follow-up. *Cent European J Urol* 2017; 70: 314–9.
44. Alizadeh F, Shahdoost AA, Zargham M, Tadayon F, Joozdani RH, Arezegar. The influence of ureteral orifice configuration on the success rate of endoscopic treatment of vesicoureteral reflux. *H Adv Biomed Res* 2013; 2: 1.
45. Choi W, Nam W, Lee C, et al. Long-term Outcomes of Endoscopic Anti-reflux Surgery in Pediatric Patients with Vesicoureteral Reflux: Urinary Tract Infection, Renal Scarring, and Predictive Factors for Success. *J Korean Med Sci* 2018; 33: e240.
46. Altuğ U, Cakan M, Yilmaz S, Yalçinkaya F. Are there predictive factors for the outcome of endoscopic treatment of grade III-V vesicoureteral reflux with dextranomer/hyaluronic acid in children? *Pediatr Surg Int* 2007; 23: 585–9.
47. Zambaiti E, Sergio M, Casuccio A, Salerno S, Cimador M. Intraoperative ultrasound-assisted approach for endoscopic treatment of vesicoureteral reflux in children. *J Pediatr Surg* 2017; 52: 1661–5.
48. Palmer LS. The role of intraoperative cystography following the injection of dextranomer/hyaluronic acid copolymer. *J Urol* 2008; 179: 1118–20.
49. López PJ, Reed F, Ovalle A, et al. Intraoperative cystography pre- and post-endoscopic treatment for vesicoureteral reflux: guaranteed success? *J Pediatr Urol* 2014; 10: 831–4.
50. Fonseca FF, Tanno FY, Nguyen HT. Current options in the management of primary vesicoureteral reflux in children. *Pediatr Clin North Am* 2012; 59: 819–34.
51. Roupakias S, Sinopidis X, Spyridakis I, Karatza A, Varvarigou A, Tsikopoulos G. The impact of our acquired experience on endoscopic injection treatment outcomes of vesicoureteral reflux during the first ten years of practice. *J Renal Inj Prev* 2021; In press (www.journalrip.com/Inpress).
52. Kirsch AJ, Perez-Brayfield MR, Scherz HC. Minimally invasive treatment of vesicoureteral reflux with endoscopic injection of dextranomer/hyaluronic acid copolymer: The Children's Hospitals of Atlanta experience. *J Urol* 2003; 170: 211–5.
53. Capozza N, Lais A, Nappo S, Caione P. The role of endoscopic treatment of vesicoureteral reflux: a 17-year experience. *J Urol* 2004; 172: 1626–8.
54. Lorenz AJ, Pippi Salle JL, Barroso U, et al. What are the most powerful determinants of endoscopic vesicoureteral reflux correction? Multivariate analysis of a single institution experience during 6 years. *J Urol* 2006; 176: 1851–5.
55. Stenbäck A, Olafsdottir T, Sköldenberg E, Barker G, Stenberg A, Läckgren G. Proprietary non-animal stabilized hyaluronic acid/dextranomer gel (NASHA/Dx) for endoscopic treatment of grade IV vesicoureteral reflux: Long-term observational study. *J Pediatr Urol* 2020; 16: 328.e1–9.
56. Routh JC, Inman BA, Reinberg Y. Dextranomer/hyaluronic acid for pediatric vesicoureteral reflux: systematic review. *Pediatrics* 2010; 125: 1010–9.
57. Elder JS, Diaz M, Caldamone AA, et al. Endoscopic therapy for vesicoureteral reflux: a meta-analysis. I. Reflux resolution and urinary tract infection. *J Urol* 2006; 175: 716–22.
58. Routh JC, Reinberg Y. Predicting success in the endoscopic management of pediatric vesicoureteral reflux. *Urology* 2010; 76: 195–8.
59. Alkan M, Ciftci AO, Senocak ME, Tanyel FC, Buyukpamukcu N. Endoscopic Treatment of Vesicoureteral Reflux in Children: Our Experience and Analysis of Factors Affecting Success Rate. *Urol Int* 2008; 81: 41–6.
60. Biočić M, Todorčić J, Budimir D, et al. Endoscopic treatment of vesicoureteral reflux in children with subureteral dextranomer/hyaluronic acid injection: a single-centre, 7-year experience. *Can J Surg* 2012; 55: 301–6.
61. Puri P, Mohanan N, Menezes M, Colhoun E. Endoscopic treatment of moderate and high grade vesicoureteral reflux in infants using dextranomer/hyaluronic acid. *J Urol* 2007; 178: 1714–6.
62. Fuentes S, Gómez-Fraile A, Carrillo-Arroyo I, Tordable-Ojeda C, Cabezalí-Barbancho D. Endoscopic Treatment of Vesicoureteral Reflux in Infants. *Can We Do It and Should We Do It? Urology* 2017; 110: 196–200.
63. Rao KL, Menon P, Samujh R, Mahajan JK, Bawa M, Malik MA, Mittal BR. Endoscopic Management of Vesicoureteral Reflux and Long-term Follow-up. *Indian Pediatr* 2018; 55: 1046–9.
64. Zambaiti E, Pensabene M, Montano V, Casuccio A, Sergio M, Cimador M. Ultrasonographic mound height as predictor of vesicoureteral reflux resolution after endoscopic treatment in children. *J Pediatr Surg* 2016; 51: 1366–9.
65. Kim H, Kim BS, Cheong HI, Cho BS, Kim KM. Long-term Results of Endoscopic Deflux Injection for Vesicoureteral Reflux in Children. *Child Kidney Dis* 2015; 19: 31–8.
66. Wang PZT, Abdelhalim A, Walia A, Wehbi E, Dave S, Khoury A. Avoiding routine postoperative voiding cystourethrogram: Predicting radiologic success for endoscopically treated vesicoureteral reflux. *Can Urol Assoc J* 2019; 13: 119–24.
67. Coletta R, Olivieri C, Briganti V, et al. Patients with a history of in-

- fection and voiding dysfunction are at risk for recurrence after successful endoscopic treatment of vesico ureteral reflux and deserve long-term follow up. *Urol Ann* 2012; 4: 19-23.
68. Puri P, Kutasy B, Colhoun E, Hunziker M. Single center experience with endoscopic subureteral dextranomer/hyaluronic acid injection as first line treatment in 1,551 children with intermediate and high grade vesicoureteral reflux. *J Urol* 2012; 188: 1485-9.
 69. Lee JN, Lee SM, Ha YS, et al. VUR timing on VCUG as a predictive factor of VUR resolution after endoscopic therapy. *J Pediatr Urol* 2016; 12: 255.e1-6.
 70. Han DS, Cambareri G, Alagiri M, Chiang G. Reflux Timing Is a Predictor of Successful Endoscopic Treatment of Vesicoureteral Reflux. *Urology* 2019; 124: 237-40.
 71. Helmy T, Sharaf D, AbdelHalim A, Hafez A, Dawaba M. Can distal ureteral diameter predict reflux resolution after endoscopic injection? *Urology* 2015; 85: 896-9.
 72. Payza AD, Hoşgör M, Serdaroğlu E, Sencan A. Can distal ureteral diameter measurement predict primary vesicoureteral reflux clinical outcome and success of endoscopic injection? *J Ped Urol* 2019; 15: 515.e1-8.
 73. Leung L, Chan IHY, Chung PHY, Lan LCL, Tam PKH, Wong KKY. Endoscopic injection for primary vesicoureteric reflux: Predictors of resolution and long term efficacy. *J Pediatr Surg* 2017; 52: 2066-9.
 74. Peters CA, Skoog SJ, Arant BS Jr, et al. Summary of the AUA Guideline on Management of Primary Vesicoureteral Reflux in Children. *J Urol* 2010; 184: 1134-44.
 75. Capozza N, Lais A, Matarazzo E, Nappo S, Patricolo M, Caione P. Influence of voiding dysfunction on the outcome of endoscopic treatment for vesicoureteral reflux. *J Urol* 2002; 168: 1695-8.
 76. Hensle TW, Reiley EA, Ritch C, Murphy A. The clinical utility and safety of the endoscopic treatment of vesicoureteral reflux in patients with duplex ureters. *J Pediatr Urol* 2010; 6: 15-22.
 77. Hunziker M, Mohanan N, Puri P. Dextranomer/hyaluronic acid endoscopic injection is effective in the treatment of intermediate and high grade vesicoureteral reflux in patients with complete duplex systems. *J Urol* 2013; 189: 1876-81.
 78. Arlen AM, Scherz HC, Filimon E, Leong T, J Kirsch AJ. Is routine voiding cystourethrogram necessary following double hit for primary vesicoureteral reflux? *J Pediatr Urol* 2015; 11: 40.e1-5.
 79. Harper L, Paillet P, Minvielle T, et al. Long-Term (>10 Years) results after endoscopic injection therapy for vesicoureteral reflux. *J Laparoendosc Adv Surg Tech A* 2018; 2: 1408-11.
 80. Stredle RJF, Dietz HG, Stehr M. Long-term results of endoscopic treatment of vesicoureteral reflux in children: comparison of different bulking agents. *Pediatr Urol* 2013; 9: 71-6.
 81. Chi A, Gupta A, Snodgrass W. Urinary tract infection following successful dextranomer/hyaluronic acid copolymer for vesicoureteral reflux. *J Urol* 2008; 179: 1966-9.
 82. Hunziker M, Mohanan N, D'Asta F, Puri P. Incidence of febrile urinary tract infections in children after successful endoscopic treatment of vesicoureteral reflux: a long-term follow-up. *J Pediatr* 2012; 160: 1015-20.